



Original Article

Interest of routine MR spectroscopic techniques for differential diagnosis between radionecrosis and progression of brain tumor lesions

Federico De Lucia^{*}, Yolene Lefebvre, Marc P. Lemort

Department of Radiology, Jules Bordet Institute, Université Libre de Bruxelles, Brussels, Belgium



ARTICLE INFO

Keywords:

MRS feasibility
Magnetic resonance spectroscopy
Routine-differential diagnosis
Brain radionecrosis
Brain tumors

ABSTRACT

Objectives: The main objective of the study is to assess the feasibility and reproducibility of routine MRS to assist in the differential diagnosis between post-radiation necrosis and tumor progression. The secondary objective is to evaluate the accuracy of the method.

Method: An additional sequence of MRS was added to the standard protocol routinely used for patient follow-up. To assess discomfort a control group was formed. The time required to perform MRS and analysis of results, and data about artefacts and technical limitations were collected. MRS results analyzed independently by two neuroradiologists were compared. The diagnostic accuracy of MRS was calculated using a composite reference standard.

Results: The experimental group included 38 patients, the control group 41. The discomfort felt during the examination, is not significantly different between the groups. The average quality of SRM is rated as low. The frequency of cerebral radionecrosis is 13 % based on the reference standard used, 54 % and 46 % based on MRS results for the two observers. The additional time is 19,5 min. There is strong inter-observer agreement. The sensitivity and specificity of MRS are respectively for the diagnosis of radionecrosis of 60 % and 45 % (PPV = 16 %NPV = 87 %), for the diagnosis of tumor tissue of 25 % and 94 % (PPV = 80 %NPV = 57%).

Conclusion: MRS is probably not applicable in routine clinical practice; however, in view of our results and the literature, in selected cases, it could be a support in the diagnosis of radionecrosis or brain tumor progression. Radionecrosis is probably underestimated.

1. Introduction

The annual incidence of primitive brain tumors in Europe, according to the RARECARE project, is 5–6 per 100,000 [1]. The annual incidence of secondary tumors in the USA based on autopsies is 83.5/100,000. Between 8.5 % and 9.6 % of patients with major neoplasia who are known to give frequent brain metastases (breast neoplasia, colorectal, kidney, lung, and melanoma) are affected; this is probably underestimated and the incidence is increasing [2]. The treatment of primitive and secondary brain tumors involves the use of systemic therapies, surgery, and radiation therapy alone or simultaneously. Radiotherapy treatments and radiosurgery can cause secondary effects. Two of these effects pose a differential diagnostic problem in brain imaging: pseudo progression, observed in early delayed phases, and radionecrosis, observed in late delayed phases [3]. Differentiation of these entities from tumor progression is a challenge in magnetic resonance imaging

(MRI). Diagnosis can be determined by combining diffusion, perfusion, magnetic resonance spectroscopy (MRS) techniques, as by comparing the area, volume, and edges of the lesions in T1 and T2 [4]. Recent literature suggests that the combination of multiple magnetic resonance imaging methods reduces the possibility of lesion misinterpretation, however prospective and longitudinal studies are required to validate multiparametric MRI [5,6]. Post-therapeutic residual or recurrent tumor in patients with primitive or secondary brain tumors are major criteria for survival [7], and accurate and rapid diagnosis is very important for proper management. Routine use of MRS maybe could benefit the patient. Our study intent to evaluate this point. Several studies [8–11] have assessed the usefulness of this method, in most cases with limited cohorts, and have not evaluated the feasibility in routine. The main objective of our work is to assess the feasibility of using MRS in routine use for the differential diagnosis between necrosis and tumor progression of brain lesions after radiotherapy or radiosurgery.

^{*} Correspondence to: avenue de levis mirepoix 6, 1090 Jette, Belgium.

E-mail address: federicodelucia507@gmail.com (F. De Lucia).

2. Materials and methods

We conducted a non-randomized prospective study that added a sequence of Chemical Shift Imaging (CSI) in MRS to usual patient's follow-up. Patients were included from June 2019 to February 2020. The inclusion criteria were: adult patients with at least one primary or secondary brain tumor lesion and treated with radiation alone or combined with surgery and/or systemic treatments. The criteria for exclusion were: patient under 18 years of age, contraindications to MRI or contraindication to gadolinium injection. MRS preparation, acquisition and time for analysis were measured, artefacts and technical limitations of the method were registered. The MRS sequence performed is a CSI multivoxel, with an echo time (TE) of 135 ms, centered on the area where the tumor(s) were located on the previous examination if it was no longer visible or properly demarcated on the current examination. A control group has been constituted with adult patients benefiting from post-contrast brain MRI in the context of assessment of an extracranial primary cancer. The perception of the exam was assessed by participants

in both groups using a numerical visual scale of discomfort calibrated from 0 to 10. The expected sample size was at least 30 patients per group.

The examinations were performed with 3 T and 1.5 T devices with administration of routine dose of Gadolinium (gadoterate at dose 0. 2 mL/kg or gadobutrol at 0.1 mL/kg dose). Two radiologists analyzed the standard images and then the MRS sequence. For the analysis of the latest, the reviewers completed a dedicated report form. Spectrum quality was assessed qualitatively according to baseline disturbance on a scale of 0–3 (0 = uninterpretable 1 = baseline very disturbed 2 = base line moderately perturbed 3 = very well).

The results of morphological sequences were compared with the results of MRS to identify a possible complementary contribution. When available, results of a composite reference standard (including all or part of the following: PET-CT methionine, PET-CT FDG, pathology, successive MRI scans, or clinical evolution) have been considered. For the interpretation of MRS sequences, each observer selected one or more voxels in the available volume and measured the values and ratios of the

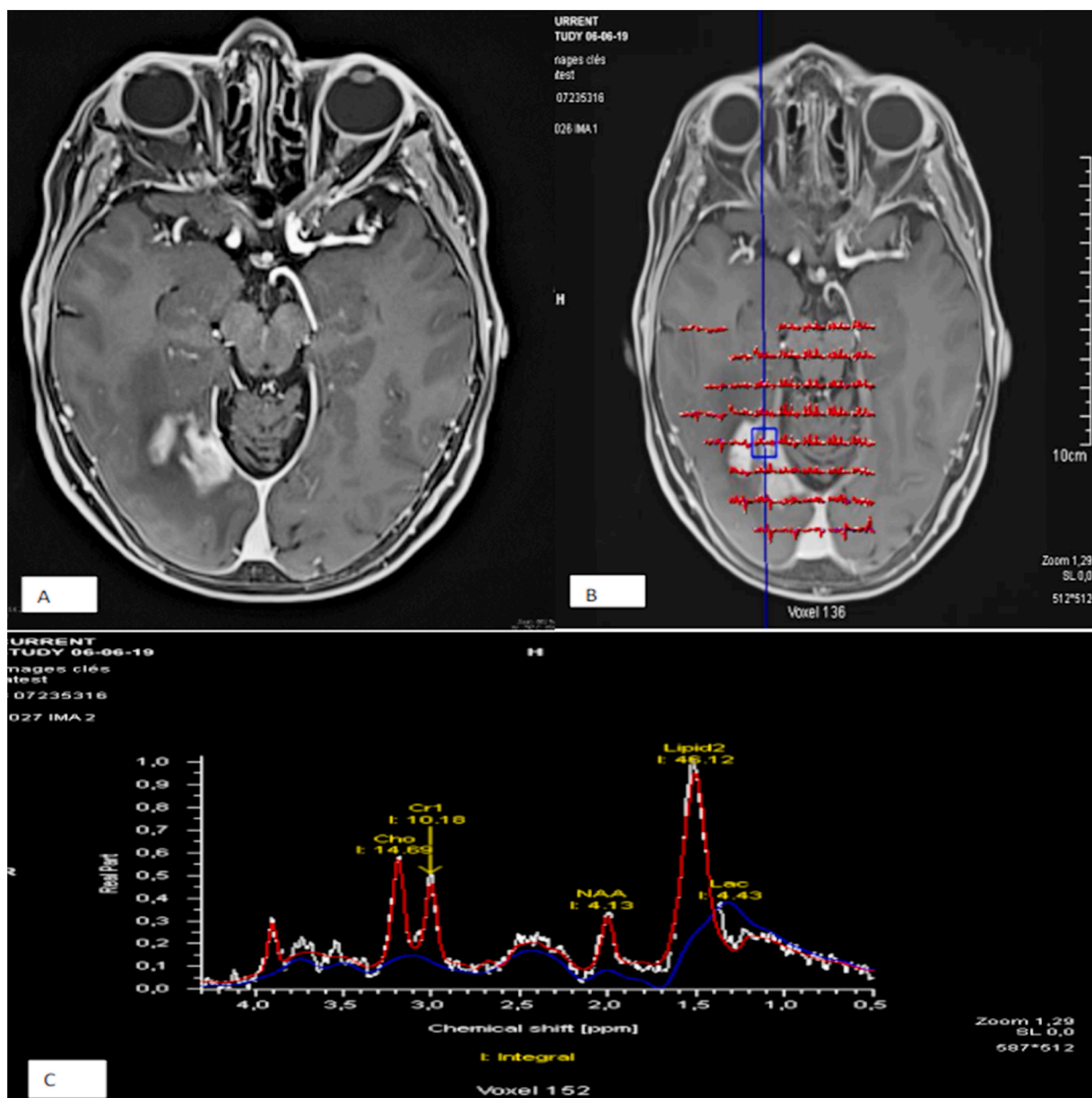


Fig. 1. Right temporo-occipital lesion, radionecrosis. A Axial T1 FAT-SAT with Gadolinium showing a contrast enhancement. B voxel chosen. C Voxel's spectrum suggesting a radionecrosis (Cho/Cr = 1,44-Cho/NAA = 3,56-Cho/Lip + Lac = 0,29).

following metabolites: choline (Cho), creatine (Cr); N-Acetyl-Aspartate (NAA), Lipid (Lip), lactate (Lac). The thresholds for ratios of these metabolites have been established in comparison with studies whose populations like our cohort [10–14]. The Cho/NAA > 1.5 and Cho/Cr > 2 ratios have been selected as thresholds for indicating tumor tissue and the Cho/(lactate + lipid) < 0.3 ratio for radionecrosis (Figs. 1, 2). Other threshold values have been tested to improve the diagnostic accuracy of MRS. A 5-point score was established, as described in Table 1.

The interobserver reproducibility assessment was evaluated by the kappa test. The hypothesis test for the assessment of a statistically significant difference in discomfort during the brain MRI examination with and without MRS is performed using a numerical visual scale and the Mann-Whitney test for independent samples. Univariate analysis was performed for comparing the two groups. Sensitivity and specificity of

MRS was calculated using the composite reference standard defined.

3. Results

The group of patients receiving the spectroscopic sequence consists of 38 individuals, Primitive tumors found are listed in Table 2.

The average time between cerebral irradiation and MRS is 1 year and 11 months, in only 3 cases (8 %) this time is less than 3 months; it is between 3 months and 1 year for 8 patients (21 %).

The control group consists of 46 patients, 5 of whom were excluded due to no tumor context. The characteristics of the two groups were compared by univariate analysis (Table 3). This analysis does not show statistically significant differences in age, sex, tumor pathology, corticoids, symptoms, and history of brain surgery.

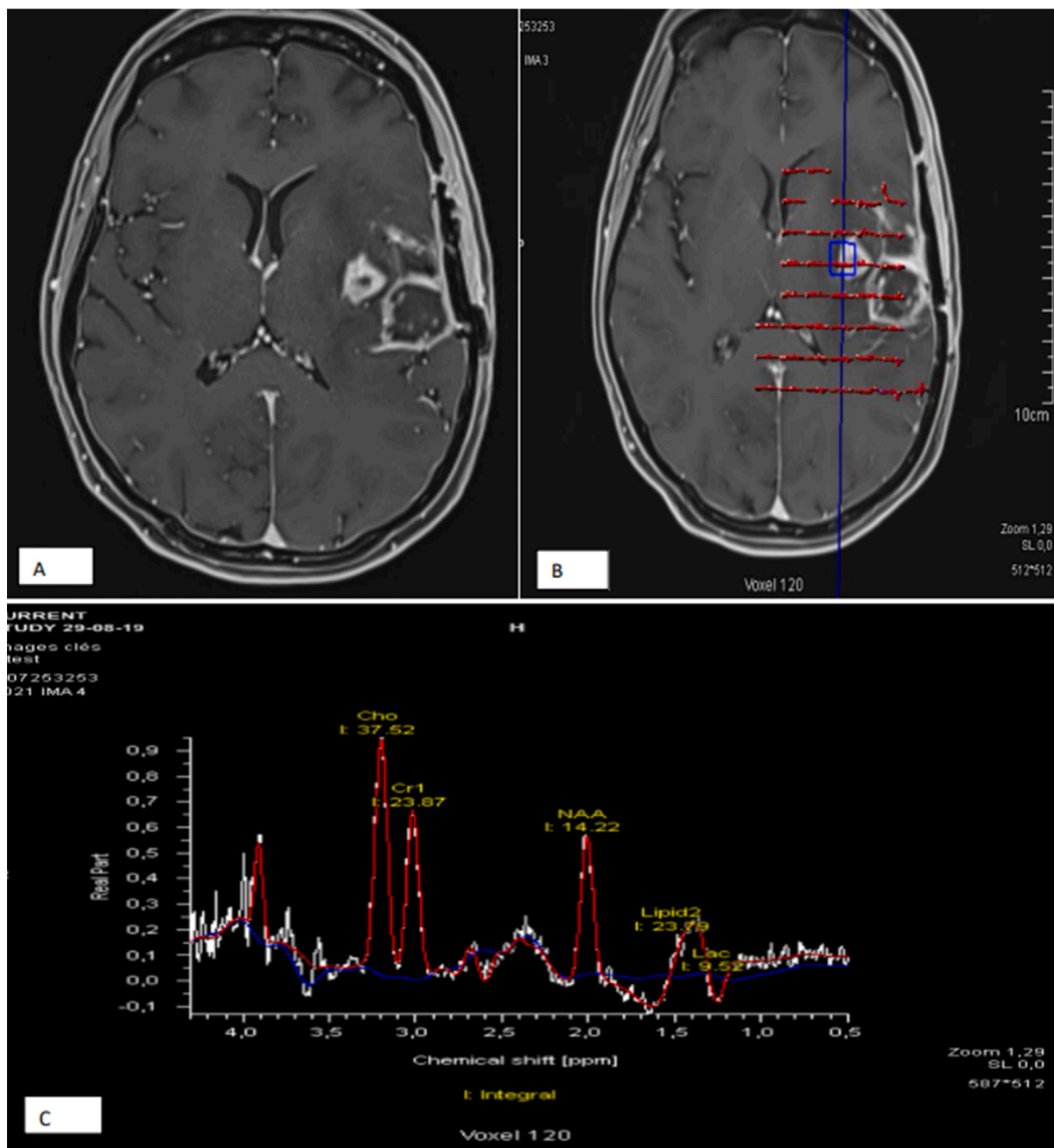


Fig. 2. Left insular lesion, glioblastoma. A Axial T1 FAT-SAT with Gadolinium showing a contrast enhancement. B voxel chosen. C spectrum indicating tumor tissues (Cho/Cr = 1,57-Cho/NAA = 2,64-Cho/Lip + Lac = 1,13).

Table 1
MRS 5-points score.

Score	MRS (thresholds successively established)	MRI MORPHOLOGICAL	Global MRI score
5 = High probability of tumor recurrence	Cho/NAA > 1.5(1.5–1.1) AND Cho/Cr > 2 (1.5–1.3) Cho/(Lip + Lac) > 0.3(0.6)	tumor tissue	3
4 = Suspicion of tumor recurrence	Cho/NAA > 1.5(1.5–1.1) OR Cho/Cr > 2(1.5–1.3) Cho/(Lip + Lac) > 0.3 (0.6)	tumor tissue	3
3 = undetermined	Cho/NAA > 1.5(1.5–1.1) OR Cho/Cr > 2(1.5–1.3) AND Cho/(Lip + Lac) < 0.3(0.6)	Radionecrosis is possible	2
2 = high probability of radionecrosis	Cho/NAA < 1.5(1.5–1.1) OR Cho/Cr < 2(1.5–1.3) AND Cho/(Lip + Lac) < 0.3(0.6)	Radionecrosis is possible	2
1 = healthy brain	Cho/NAA < 1.5(1.5–1.1) AND Cho/Cr < 2 (1.51.3) AND Cho/(Lip + Lac) > 0.3(0.6)	Healthy brain	1

Table 2
Primitive tumors.

Primary tumors	n (%)
Lung (3 SCLC, 12 ADC, 1 SCC)	16(42)
Breast	10(26)
Melanoma	6(16)
Cerebral (2 glioblastoma, 1 épendymoma, 1 astrocytoma)	4(10.5)
Clear cell renal carcinoma	1(2.75)
Extragenital germ cell tumor	1(2.75)

For the discomfort experienced during the examination, the Mann-Whitney test shows no statistically significant difference between the two groups, with an average assessment of discomfort on a scale of one to ten values 1 (0–4) for the control group and 2 (0–4) for the experimental group.

For the experimental group. One examination resulted in a technical failure. Two examinations are noted as presenting magnetic susceptibility artefacts.

The average time required to prepare and acquire the CSI spectroscopic sequence (reported for 34 of the 37 exams) was 14 min. It includes the acquisition of the 3D VIBE sequence necessary for tuning the CSI sequence, automatic shim, manual shim, water adjustment to saturate the signal of the water and the CSI acquisition. The time required to analyze the spectroscopic sequence is an average of 5 min for one observer and 6 min for the other; this difference is not statistically significant (Mann-Whitney test $p = 0.0537$). An observer reports 2 uninterpretable MRS and 2 MRS at the limit of interpretability. There is a strong inter-observer ($K = 0.75$) and statistically significant ($p \leq 0.001$) concordance in the choice of region to be studied by spectroscopy (48 % of patients have multiple metastases). The inter-observer concordance for the quality of spectroscopic sequences (based on an assessment of 0–3) is very low ($K = 0.13$).

The average MRS quality defined by both observers varies between a highly disturbed baseline and a moderately disturbed baseline. The proportion of uninterpretable or badly interpretable MRS sequences is 10 % overall.

The distribution following the magnetic field intensity (1.5 T or 3.0 T) is homogeneous in the sample and does not significantly affect the qualitative assessment of observers (p -value = 0.52 for one observer and 0.80 for the other).

The inter-observer concordance for the reading of spectroscopy sequences based on the MRS score is strong ($K = 0.66$) and statistically

significant ($p = 0.001$).

Table 4 show the result based on reference examination and MRS (with the first set thresholds initially established) for each observer. Three of five patients who performed a methionine PET-CT that suggested radionecrosis were treated with immunotherapy. Among patients treated with immunotherapy, the rate of MRS radionecrosis is 41 % (7/17) for one observer and 35 % (6/17) for the other. The main location of the targeted lesions is distributed for the observers as follows: 36 % (15/41) in the frontal lobe, 12 % (5/41) and 20 % (8/41) in the occipital lobe, 20 % (8/41) in the cerebellum.

The best sensitivity and specificity of MRS between observers, calculated using the composite reference standard for the diagnosis of radionecrosis and tumor tissue, is shown for the different thresholds in Table 5.

4. Discussion

The technique of multi-voxel MRS (Spectroscopic Imaging or CSI) seemed to be the most suitable for our study, allowing the study of metabolites distribution in a larger region compared to single-voxel technology, however, this technique is more sensitive to metal artefacts, its acquisition time is longer, and it performs less well in several brain regions: posterior fossa anterior part of the temporal lobe, frontal lobe [15]. In our study, 56 % of the lesions are in these regions. The localization of lesions is probably one of the factors that has influenced the quality of MRS. Other techniques of improvement, such as the reduction of the shim field of view (FOV) and the focus on the part of lesion to be examined may be considered [16,17]. The training of operator for this technique should be improved if it is to be used in routine.

The additional acquisition time of 14 min, the reading time of 5–6 min, and the failure rate of 10% argue against routine use of MRS. The single voxel technique has not been explored. It allows for a shorter acquisition time, a better homogeneity of the field, but requires a precise knowledge of the part of lesion to be studied [15]. The use of the two techniques in context could improve the time and quality limitations highlighted here. The reproducibility of brain MRI sequences between MRI system manufacturers is good despite the absence of international standardized protocols [18]. Studies addressing only metastatic lesions versus radionecrosis are small, with varying results and metabolites ratio thresholds, Huang et al. [10] showed a sensitivity of 33 % and a specificity of 100 %, or Menoux et al. [11] 92 % and 56 % respectively. In the meta-analysis of Wang et al., the prevalence of radionecrosis varies from 14 % to 45 % depending on the studies [8].

Spectroscopy in oncological brain imaging has an interest in the follow-up and diagnosis of both primary and secondary tumor lesions. In gliomas, it allows for the molecular identification of certain subtypes of gliomas [19], it also allows correlation to the Ki67 antigen expression [20], and an increase of more than 20 % choline is associated with tumor progression [21]. About the choice of thresholds, our aim was to improve the sensitivity for radionecrosis and the specificity for tumor tissue, in addition the specificity of 90 % and the 80 % VPP for tumor tissue detection (Fig. 2) demonstrate the usefulness of MRS for the follow-up of brain tumors and differential diagnosis between pseudo progression, radionecrosis and neoplastic tissue. However, the concomitant presence of tumoral and necrotic tissue is possible [22], and molecular imaging such as MRS can confirm this entity. Considering literature data, MRS scores, and the relative quality of reference standard, the prevalence of radionecrosis in our cohort could be above 13 %.

Recent literature suggests that the combination of multiple magnetic resonance imaging and advanced imaging methods reduces the possibility of lesion misinterpretation and increase sensitivity, specificity and accuracy to differentiate tumor progression and treatment-related changes however prospective and longitudinal studies are required to validate and standardize multiparametric methods [6,23], the aim of our study was to assess the feasibility of using MRS in routine use when

Table 3
Univariate analysis of the two groups.

Variables	Experimental group			Control group			p-value
	n (%)	Average (DS)	P50 (P25–P75)	n (%)	Average (DS)	P50 (P25–P75)	
Age (years)		56.5(13)			58 (13)		0.65*
Sex							
	23 (60)			22 (54)			0.54**
Female	15 (40)			19 (46)			
Male							
Cerebral surgery							
Yes	10 (26)			5 (12)			0.11**
No	28 (74)			36(88)			
Corticotherapy							
Yes	4 (10,5)			4 (10,5)			1**
No	34 (89,5)			37 (89,5)			
Orthopnea							
Yes	1 (3)			1 (3)			1***
No	37 (97)			40 (97)			
MRI							
MRI 3 T	19 (50)			14 (34)			0.15**
MRI 1.5 T	19 (50)			27 (66)			
Neurological symptoms							
Yes	6 (16)			11(29)			0.17**
No	32 (84)			30(71)			
Neoplasias							
	16 (42,1)			19 (46,3)			0.06***
Pulmonary	10 (26,3)			8 (19,5)			
Breast	6 (15,8)			5 (12,2)			
Melanoma	4 (10,5)			0 (0)			
Glioma	2 (5,3)			9 (22)			
Other							
Discomfort (EVN)			2(0-4)			1(0-4)	0.84****

* Test t of Student.

** Test Chi2.

*** Test exact of Fisher.

**** Test of Mann-Whitney.

Table 4
Results based on reference standard and MRS SCORE (with the first set thresholds initially established) for each observer.

Conclusion	MRS SCORE	Observer1 (%)	Observer2 (%)	Reference standard (%)
Radionecrosis	2	20/37(54)	17/37(46)	5/38(13)
Tumor	3-4-5	6/37(16)	5/37(14)	25/38(66)
Healthy brain	1	11/37(30)	15/37(40)	8/38(21)

Table 5
The best sensitivity and specificity of MRS with different thresholds, calculated using the composite reference standard for the diagnosis of radionecrosis and tumor tissue.

Thresholds	Radionecrosis	Tumoral tissue
1) Cho/NAA = 1.5Cho/Cr = 2 Cho/(Lip + Lac) = 0.3	Se = 60 %	Se = 25 %
	Sp = 45 %	Sp = 94 %
	VPP = 16 %	VPP = 80 %
	VPN = 87 %	VPN = 57 %
	Se = 75 %	Se = 31 %
2) Cho/NAA= 1.5Cho/Cr = 1.5 Cho/(Lip + Lac) = 0.6	Sp = 54 %	Sp = 89 %
	VPP = 20 %	VPP = 71 %
	VPN= 93 %	VPN = 59 %
	Se = 67 %	Se = 62.5 %
	Se = 55 %	Sp = 64 %
3) Cho/NAA = 1.1Cho/Cr = 1.3 Cho/(Lip + Lac) = 0.6	VPP = 14 %	VPP = 67 %
	VPN = 96 %	VPN = 60 %

there was an enhancing lesion in the area that was previously treated, most of the time for the follow-up of brain metastatic disease. A systematic multiparametric approach was not performed and perfusion and diffusion data are not available for all patients.

Radiological investigations involve anxiety in oncological patients and not, the anxiety activates the autonomic nervous system causing hyperactivity, harmful to the quality of radiological examinations [24], in this study the addition of a sequence of MRS has not shown a difference on comfort of patients during the examination.

5. Conclusion

MRS is probably not a clinical routine technique due to the methodological difficulties, failure rate and the extra time required. However, for selected cases, considering the results of the literature, the inter-observer concordance, the small impact on comfort of patients, MRS could add arguments for the diagnosis of cerebral radionecrosis, and detection of persistent or recurrent brain tumor. Radionecrosis is probably underestimated. Standardized metabolites thresholds and reports for MRS remain to be defined.

CRediT authorship contribution statement

Federico De Lucia, Yolene Lefebvre, Marc Lemort: Conceptualization, Methodology, Data curation, Writing – original draft, Visualization, Investigation, Writing – review & editing. **Marc Lemort, Yolene Lefebvre:** Supervision.

Ethical Statement

The study was approved by the Jules Bordet Institute ethics committee under the number CE3010.

The study was conducted in accordance with the principles embodied in the Declaration of Helsinki and in accordance with local statutory requirements.

All participants gave written informed consent to participate in the study.

Funding Statement

The authors received no financial support for the research, authorship, and/or publication of this article.

Conflict of Interest

The authors have no conflict of interest.

References

- [1] E. Crocetti, A. Trama, C. Stiller, et al., Epidemiology of glial and non-glial brain tumours in Europe, *Eur. J. Cancer* 48 (10) (2012) 1532–1542, <https://doi.org/10.1016/j.ejca.2011.12.013>.
- [2] E. Tabouret, L. Bauchet, A. Carpentier, Épidémiologie des métastases cérébrales et tropisme cérébral, *Bull. Cancer* 100 (2013) 57–62, <https://doi.org/10.1684/bdc.2012.1681>.
- [3] J. Fink, D. Born, M.C. Chamberlain, Radiation necrosis: relevance with respect to treatment of primary and secondary brain tumors, *Curr. Neurol. Neurosci. Rep.* 12 (3) (2012) 276–285, <https://doi.org/10.1007/s11910-012-0258-7>.
- [4] A. Raimbault, X. Cazals, M.A. Lauvin, et al., Radionecrosis of malignant glioma and cerebral metastasis: a diagnostic challenge in MRI, *Diagn. Interv. Imaging* 95 (10) (2014) 985–1000, <https://doi.org/10.1016/j.diii.2014.06.013>.
- [5] N. Verma, M.C. Cowperthwaite, M.G. Burnett, et al., Differentiating tumor recurrence from treatment necrosis: a review of neuro-oncologic imaging strategies, *Neuro Oncol.* 15 (5) (2013) 515–534, <https://doi.org/10.1093/neuonc/nos307>.
- [6] V. Sawlani, N. Davies, M. Patel, et al., Evaluation of response to stereotactic radiosurgery in brain metastases using multiparametric magnetic resonance imaging and a review of the literature, *Clin. Oncol.* 31 (1) (2019) 41–49, <https://doi.org/10.1016/j.clon.2018.09.003>.
- [7] M.K. Bucci, A. Maity, A.J. Janss, et al., Near complete surgical resection predicts a favorable outcome in pediatric patients with nonbrainstem, malignant gliomas: results from a single center in the magnetic resonance imaging era, *Cancer* 101 (14) (2004) 817–824, <https://doi.org/10.1002/cncr.20422>.
- [8] W. Wang, Y. Hu, P. Lu, et al., Evaluation of the diagnostic performance of magnetic resonance spectroscopy in brain tumors: a systematic review and meta-analysis, *PLoS One* 9 (11) (2014), e112577, <https://doi.org/10.1371/journal.pone.0112577>.
- [9] M.T. Chuang, Y.S. Liu, Y.S. Tsai, et al., Differentiating radiation-induced necrosis from recurrent brain tumor using MR perfusion and spectroscopy: a meta-analysis, *PLoS One* 11 (1) (2016), e0141438, <https://doi.org/10.1371/journal.pone.0141438>.
- [10] J. Huang, A.M. Wang, A. Shetty, et al., Differentiation between intra-axial metastatic tumor progression and radiation injury following fractionated radiation therapy or stereotactic radiosurgery using MR spectroscopy, perfusion MR imaging or volume progression modeling, *Magn. Reson. Imaging* 29 (7) (2011) 993–1001, <https://doi.org/10.1016/j.mri.2011.04.004>.
- [11] I. Menoux, G. Noël, D. Antoni, et al., PET scan and NMR spectroscopy for the differential diagnosis between brain radiation necrosis and tumour recurrence after stereotactic irradiation of brain metastases: place in the decision tree, *Cancer Radiother.* 21 (5) (2017) 389–397, <https://doi.org/10.1016/j.canrad.2017.03.003>.
- [12] E. Matsusue, J.R. Fink, J.K. Rockhill, et al., Distinction between glioma progression and post-radiation change by combined physiologic MR imaging, *Neuroradiology* 52 (4) (2010) 297–306, <https://doi.org/10.1007/s00234-009-0613-9>.
- [13] M.R. Anbarloui, S.M. Ghodsi, A. Khoshnevisan, et al., Accuracy of magnetic resonance spectroscopy in distinction between radiation necrosis and recurrence of brain tumors, *Iran. J. Neurol.* 14 (1) (2015) 29–34.
- [14] T. Kimura, K. Sako, T. Gotoh, et al., In vivo single-voxel proton MR spectroscopy in brain lesions with ring-like enhancement, *NMR Biomed.* 14 (6) (2001) 339–491, <https://doi.org/10.1002/nbm.711>.
- [15] P.B. Barker, A. Bizzi, N. De Stefano, et al., Pulse sequences and protocol design, in: P.B. Barker, A. Bizzi, N. De Stefano, et al. (Eds.), *Clinical MR Spectroscopy: Techniques and applications*, Cambridge University Press, Cambridge, 2010, pp. 19–33.
- [16] J. Stockmann, L. Wald, *NeuroImage In vivo B0 field shimming methods for MRI at 7 T*, *Neuroimage* 168 (2018) 71–87, <https://doi.org/10.1016/j.neuroimage.2017.06.013>.
- [17] B. Van Den Bergen, C. Van Den Berg, D. Klomp, et al., SAR and power implications of different RF shimming strategies in the pelvis for 7 T MRI, *Magn. Reson. Imaging* 30 (1) (2009) 194–202, <https://doi.org/10.1002/jmri.21806>.
- [18] M. Považan, M. Mikkelsen, A. Berrington, et al., Comparison of multivendor single-voxel MR spectroscopy data acquired in healthy brain at 26 sites, *Radiology* 295 (1) (2020) 171–180, <https://doi.org/10.1148/radiol.2020191037>.
- [19] G. Öz, J. Alger, P. Barker, et al., Clinical proton MR spectroscopy in central nervous system disorders, *Radiology* 270 (3) (2014) 658–679, <https://doi.org/10.1148/radiol.13130531>.
- [20] R. Guillemin, C. Menuel, H. Duffau, et al., Proton magnetic resonance spectroscopy predicts proliferative activity in diffuse low-grade gliomas, *J. Neurooncol.* 87 (2) (2008) 181–187, <https://doi.org/10.1007/s11060-007-9508-y>.
- [21] G. Tedeschi, N. Lundbom, R. Raman, et al., Increased choline signal coinciding with malignant degeneration of cerebral gliomas: a serial proton magnetic resonance spectroscopy imaging study, *J. Neurosurg.* 87 (4) (1997) 516–524, <https://doi.org/10.3171/jns.1997.87.4.0516>.
- [22] S. Ritu, V. Surjith, J. Rojymon, et al., Radiation necrosis in the brain: imaging features and differentiation from tumor recurrence, *Radiographics* 32 (5) (2012) 1343–1359, <https://doi.org/10.1148/rg.325125002>.
- [23] D. Qin, G. Yang, H. Jing, et al., Tumor progression and treatment-related changes: radiological diagnosis challenges for the evaluation of post treated glioma, *Cancers* 14 (2022) 3771, <https://doi.org/10.3390/cancers14153771>.
- [24] G. Lo Re, R. De Luca, F. Muscarneri, et al., Relationship between anxiety level and radiological investigation. Comparison among different diagnostic imaging exams in a prospective single-center study, *Radiol. Med.* 121 (10) (2016) 763–768, <https://doi.org/10.1007/s11547-016-0664-z>.