


Contents lists available at [ScienceDirect](https://www.sciencedirect.com)

Brain, Behavior, & Immunity - Health

journal homepage: www.editorialmanager.com/bbih/default.aspx

Review

Neurological involvement in SARS-CoV-2 infection: A clinical systematic review

Pasquale Scoppettuolo^{a,*}, Serena Borrelli^b, Gilles Naeije^c^a Department of Neurology, Centre Hospitalier du Valais Romand, Sion, Switzerland^b Department of Neurology, CHU-Brugmann, Université Libre de Bruxelles, Brussels, Belgium^c Department of Neurology, CHU-Hôpital Erasme, Université Libre de Bruxelles, Brussels, Belgium

ARTICLE INFO

Keywords:

SARS-CoV-2

Coronavirus

Neurological involvement

Neuroinvasion

Review

ABSTRACT

Objective: Reports of neurological involvement during Severe Acute Respiratory Syndrome Coronavirus-2 (SARS-CoV-2) infection course are increasingly described. The aim of this review is to provide a clinical approach of SARS-CoV-2 neurological complications based on the direct or indirect (systemic/immune-mediated) role of the SARS-CoV-2 in their genesis.

Methods: A review of the current literature has been carried out up to May 20th 2020 according to the PRISMA guidelines. All case series and reports of adult neurological manifestations associated to SARS-CoV-2 published in English were considered. Review and fundamental research studies on Coronaviruses neuroinvasive potential were analyzed to support pathogenic hypothesis and possible underlying mechanisms. Clinical patterns were subdivided into three groups according to putative underlying mechanisms: direct invasion of central or peripheral nervous system, systemic disorders leading to acute CNS injuries and post-infectious neurological syndromes (PINS).

Results: Sixteen case series and 26 case reports for a total of 903 patients were identified presenting with neurological involvement during SARS-CoV-2 infection. Hypo/anosmia and dys/ageusia were found in 826 patients and mainly attributed to direct viral invasion. Cerebrovascular complications occurred in 51 patients and related to viral infection associated systemic inflammation. PINS were described in only 26 patients. A wide heterogeneity of these reports emerged concerning the extension of the clinical examination and ancillary exams performed.

Conclusions: Neurological complications of SARS-CoV-2 are mainly related to olfactory and gustatory sensory perception disorders through possible direct nervous system invasion while cerebrovascular disease and PINS are rare and due to distinct and indirect pathophysiological mechanisms.

1. Introduction

Human Coronaviruses (CoVs) cause respiratory and enteric disease in rodents, cats, pigs and humans (Desforges et al., 2019). The end of 2019 has been marked by the transmission and spread of a novel Coronavirus (2019-nCoV) (Zhu et al., 2020) and its related severe acute respiratory syndrome (SARS-CoV-2) to the human species in Hubei region, China (Wang et al., 2020). Clinical picture in most patients is mild, with flu-like symptoms like fever, cough and myalgia but in about one quarter of cases (Huang et al., 2020) the virus lead to severe acute respiratory distress syndrome (ARDS) that requires hospital-care and invasive ventilation in intensive care unit (ICU) for severe cases (Zhou et al., 2020). In a subset

of those, ranging from 3 to 4%, the infection can lead to multiorgan failure (MOF) and death (Nath, 2020).

The fast outbreak of the virus in Europe and United States in the beginning of 2020 multiplied the number of infected people and the World Health Organization (WHO) declared SARS-CoV-2 infection pandemic on March 11th (WHO, 2020). With the increasing number of cases, other clinical manifestations than ARDS and respiratory tract infection, like anosmia, have been described allowing the identification of new cases and their prompt isolation (Rothe et al., 2020). In northern Italy, the epicentre of the European epidemic, some clinicians began to identify additional central nervous system involvement that could lead to worse outcome in infected patients, and warned about the acute neurological complaints in respiratory affected people, especially in endemic areas (Talan, 2020).

* Corresponding author. Avenue du Champsec 80, 1951, Sion, Switzerland.

E-mail address: pasquale.scoppettuolo@gmail.com (P. Scoppettuolo).

<https://doi.org/10.1016/j.bbih.2020.100094>

Received 30 May 2020; Accepted 3 June 2020

Available online 6 June 2020

2666-3546/© 2020 The Author(s). Published by Elsevier Inc. This is an open access article under the CC BY-NC-ND license (<http://creativecommons.org/licenses/by-nc-nd/4.0/>).

Glossary	
SARS-CoV-2	Severe acute respiratory syndrome coronavirus 2
PINS	Post-infectious neurological syndrome
PRISMA	Preferred Reporting Items for Systematic Reviews and Meta-Analysis
CoV	Coronavirus
2019-nCoV	2019 novel coronavirus
ARDS	acute respiratory distress syndrome
ICU	intensive care unit
MOF	multiorgan failure
WHO	World Health Organization
COVID-19	Coronavirus disease 2019
CNS	Central nervous system
SARS	Severe acute respiratory syndrome
MERS	Middle East Respiratory Syndrome
CVT	cerebral venous thrombosis
GBS	Guillain-Barré syndrome
AHNE	acute hemorrhagic necrotizing encephalitis
MFS	Miller Fisher syndrome
CSF	cerebrospinal fluid
ACE2	angiotensin-converting enzyme 2
BBB	Blood Brain Barrier
HCoV-O43	Human Coronavirus OC43
RT-PCR	Reverse transcriptase-polymerase chain reaction
FLAIR	Fluid Attenuated Inversion Recovery

The aim of this review is to provide a clinical and pathophysiological approach to SARS-CoV-2 neurological complications based on the direct or indirect (systemic/immuno-mediated) putative role of the SARS-CoV-2 in their genesis.

2. Methods

This review has been carried out according to the PRISMA statement (Moher et al., 2009) (Fig. 1). PubMed, Scopus and Cochrane Review

databases were screened (Supplementary data, Tables 1–2) from December 1st 2019 to May 20th 2020, including all case series, case reports and pre-print proofs about novel Coronavirus 2019 (nCoV-2019) related disease (COVID-19). The possible neurological symptoms/manifestations during the clinical course and the main features of different cases were sought by the authors. Additional relevant publications were identified through references of the included reports or by manual research on the journal websites. Only articles in English were analyzed. The quality of articles was assessed according to the American Academy

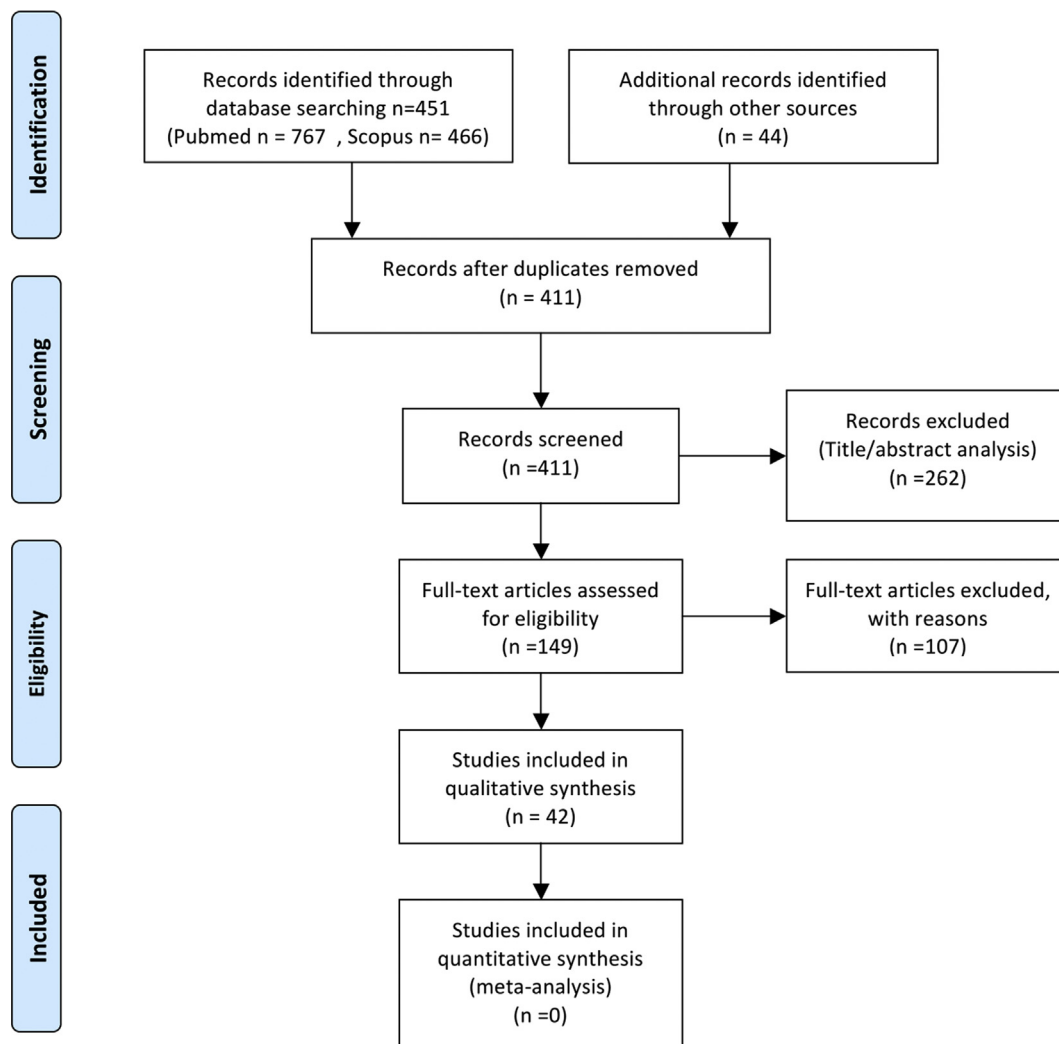


Fig. 1. PRISMA Flow diagram presenting study selection.

of Neurology criteria for classification of evidence in studies of causation (Gronseth et al., 2017). Online surveys without clinical examination performed by a physician were excluded.

The search strategy combined the following medical heading and free-text terms: "COVID-19" OR "Coronavirus" OR "SARS-CoV-2" AND "brain" OR "neurological" OR "CNS". The same procedure was carried out for "SARS" OR "SARS-CoV-1" OR "MERS" AND "brain", OR "neurological" OR "CNS" (Supplementary data, Tables 1–2). Most recent articles, not yet indexed on PubMed but available on the journal websites and papers under review in peer-reviewed journals were also considered (Fig. 1).

Study selection was performed by two researchers (PS and SB), involving a third researcher (GN) for quality assessment and agreement. Numbers of studies considered were noted in an Excel document and tables were built with Word (Supplementary data, Tables 1–2).

For all studies, characteristics of participants (age, gender, confirmed SARS-CoV-2 infection, clinical examination), ancillary exams and outcome data were extracted.

3. Data availability

Title of all papers read, results of database research and publication plan are available for reviewer upon reasonable request.

4. Results

Using our criteria, 42 articles (16 case series and 26 case reports) were retrieved (Fig. 1), corresponding to 903 patients presenting with neurological involvement in SARS-CoV-2 infection.

Eight hundred and twenty six patients presenting with neurological involvement compatible with a virus direct invasion of the nervous system were retrieved consisting of four case series (Moein et al., 2020; Lechien et al., 2020; Giacomelli et al., 2020; Mao et al., 2020) and four case reports (Eliezer et al., 2020; Galougahi et al., 2020; Gane et al., 2020; Ollarves-Carrero et al., 2020) for a total number of 445 patients presenting with hypo/anosmia, one case series (Mao et al., 2020) for a total number of three patients presenting with amblyopia likely due to optic nerve involvement, one case report (Wei et al., 2020) of a patient presenting with third cranial nerve involvement, three case series (Lechien et al., 2020; Giacomelli et al., 2020; Mao et al., 2020) for a total number of 371 patients presenting with dys/ageusia, one case report (Li et al., 2020a) of a patient presenting with symptoms of Ondine curse syndrome compatible with a brainstem involvement, four case reports (Moriguchi et al., 2020; Sun and Guan, 2020; Hanna Huang et al., 2020; Al-Olama et al., 2020) of patients presenting with meningo-encephalitis and one case report (Zhao et al., 2020a) of a patient presenting with symptoms compatible with myelitis.

Fifty one patients presenting with neurological involvement probably secondarily to systemic disorders during sepsis: seven case series (Li et al., 2020b; Klok et al., 2020; Helms et al., 2020; Avula et al., 2020; Oxley et al., 2020; Beyrouiti et al., 2020; Lodigiani et al., 2020) and one case report (Goldberg and Goldberg, 2020) for a total number of 41 patients presenting with ischemic stroke, one case series (Li et al., 2020b) and one case report (Sharifi-Razavi et al., 2020) for a total number of two patients presenting with hemorrhagic stroke, one case series (Li et al., 2020b) with one patient presenting with cerebral venous thrombosis (CVT), one case report of a patient with subarachnoid hemorrhage (Muhammad et al., 2020) and two cases from one case series (Mao et al., 2020) and one case report (Balloy et al., 2020) presenting with seizures. Finally, radiological signs of brain endotheliopathy were found in four decedents out of 20 in a post-mortem MRI study (Coolen et al., 2020).

Twenty-six patients presenting with neurological involvement probably due to a post-infectious neurological syndrome (PINS) (Marchioni et al., 2013): 13 patients with a Guillain-Barré syndrome (GBS) (Zhao et al., 2020b; Padroni et al., 2020; Coen et al., 2020; Sedaghat and Karimi, 2020; Virani et al., 2020; Toscano et al., 2020; Alberti et al., 2020; Otmani et al., 2020; Camdessanche et al., 2020), one patient with

acute hemorrhagic necrotizing encephalitis (Poyiadji et al., 2019) (AHNE), one patient with central nervous system (CNS) demyelinating lesions (Zanin et al., 2020), two case series and one case report for a total number of nine PINS associated encephalitis (Bernard-Valnet et al., 2020; Dogan et al., 2020; Pilotto et al., 2020), one patient with a Miller Fisher syndrome (MFS) (Gutiérrez-Ortiz et al., 2020) and one patient with a polyneuritis cranialis (Gutiérrez-Ortiz et al., 2020).

Table 1 and Fig. 2 summarized different neurological involvements and pathogenic mechanisms supposed.

5. Discussion

The neurological tropism of coronaviruses is well described (Bohmwald et al., 2018), in particular for SARS-CoV-1 that shares highly similar genomic sequences with SARS-CoV-2 (Wu et al., 2020; Zhu et al., 2020) and likely similar biological properties. In animal models, SARS-CoV penetrates in the brain through the olfactory bulb and, from there, spreads within the CNS (Netland et al., 2008), cerebrospinal fluid (CSF) (Hung et al., 2003; Lau et al., 2004), hypothalamus and cortical neurons (Ding et al., 2003; Xu et al., 2005). In the brainstem, the ambiguous nucleus and the solitary tract, responsible for respiratory control, can be targeted by coronaviruses, hinting toward central hypoventilation mechanisms likely contributing to SARS-CoV-2 respiratory failure (Li et al., 2020a). Apart from a direct virus invasion, SARS-CoV-2 neurological damages can be related to the systemic inflammatory response, due to the innate immunity activation that leads in severe cases to a “cytokine storm” responsible for acute thrombo-embolic complications and post-infectious dysimmune inflammatory neurological illnesses that likely involve both cell mediated immune reaction and humoral immune system.

1. SARS-CoV-2 direct nervous system invasion

Direct SARS-CoV-2 invasion of nervous system is probably due to two non-exclusive mechanisms: a trans-neuronal retrograde pathway (Desforges et al., 2019) and a hematogenous invasion, with transcytosis or direct infection of endothelial or epithelial cells of the Blood Brain Barrier (BBB) favoured by their expression of angiotensin-converting enzyme (ACE) 2 receptors (Bohmwald et al., 2018).

The trans-neuronal retrograde pathway partly accounts for anosmia, one of the most reported symptom in SARS-CoV-2 infection throughout the world. Anosmia in SARS-CoV-2 is likely due to both transmission impairment, by obstructive inflammation of olfactory clefts, that prevents odorant molecules from reaching the olfactory epithelium (Eliezer

Table 1
Neurological involvement in SARS-CoV-2 according to putative underlying mechanisms.

Direct neurological system invasion		Systemic disorders leading acute CNS injuries	PINS
CNS	PNS		
Hypo/anosmia (I nerve palsy)	Dys/ageusia (VII nerve palsy)	Stroke (ischemic and hemorrhagic)	GBS
Optic nerve (II nerve palsy)	III nerve palsy	CVT	MFS
Ondine curse syndrome		Subarachnoid hemorrhage	AHNE
Meningo/encephalitis		Seizures and status epilepticus	Autoimmune parainfectious encephalitis
Myelitis			Demyelinating central lesions

CNS: central nervous system; PNS: peripheral nervous system; PINS: post-infectious neurological syndrome; CVT: cerebral venous thrombosis; GBS: Guillain-Barré syndrome; MFS: Miller Fisher syndrome; AHNE: acute hemorrhagic necrotizing encephalopathy.

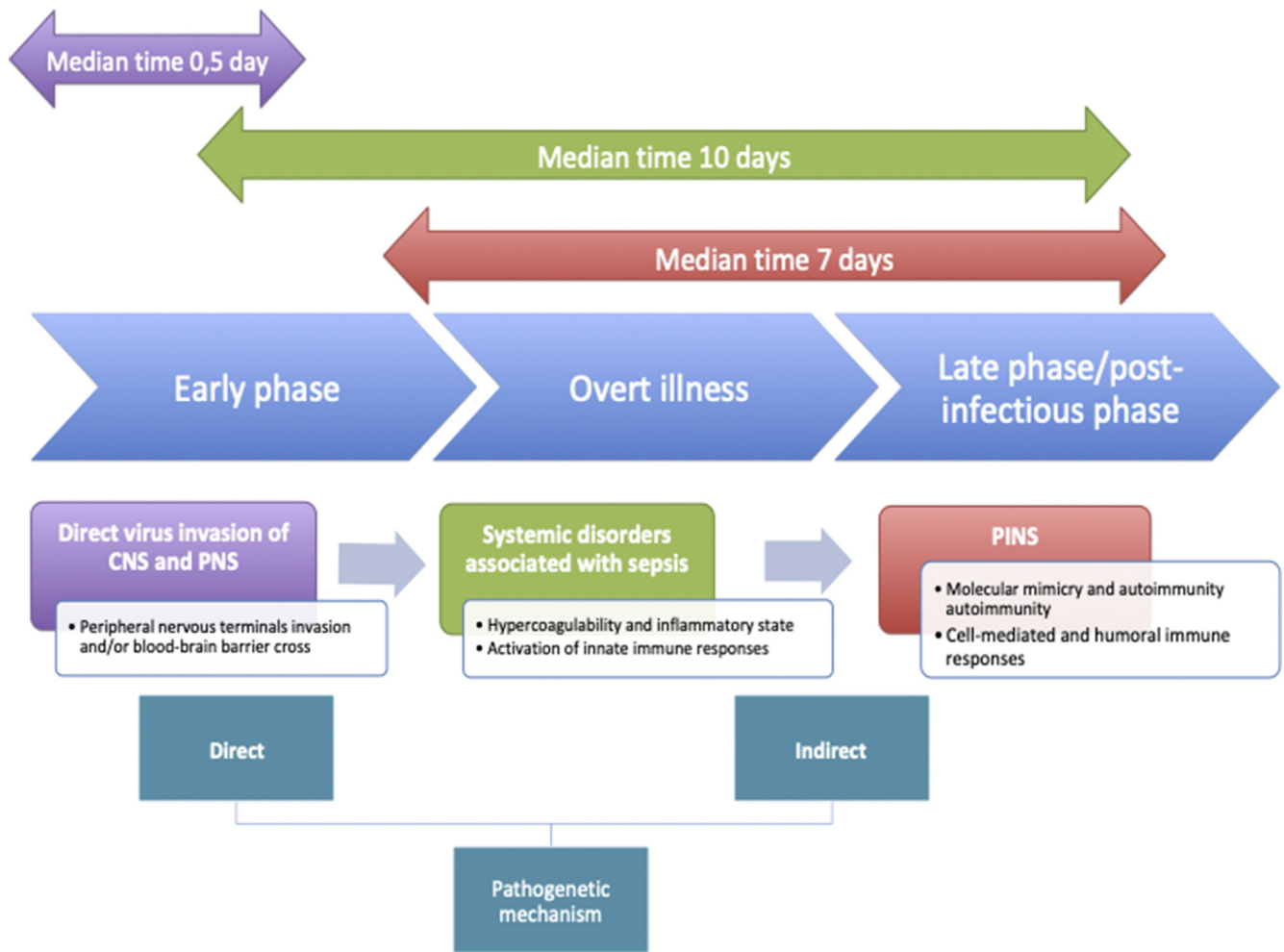


Fig. 2. Pathogenic mechanisms (direct invasion, systemic disorders associated with sepsis and PINS) according to the timeline of SARS-CoV-2 infection (early, overt illness and late/post-infectious phase), classified as direct or indirect (see text for details). PINS: post-infectious neurological syndrome.

et al., 2020), and to perception alteration, through direct virus invasion of olfactory sensory neurons. From the olfactory primary sensory neurons SARS-CoV-2 can use the active retrograde transport axonal machinery to reach the anterior cranial fossa across the cribriform plate of the ethmoidal bone as a front door for CNS invasion. This pathway was demonstrated in murine models of Human Coronavirus OC43 (HCoV-O43) infection (St-Jean et al., 2004) where virus antigens were detected in the olfactory bulb three days after the infection, with no traces in perivascular blood cells. Then virus may spread later throughout the whole brain tissue, causing acute encephalitis and finally animal death.

Clinically, olfactory and taste disorders are found between 33% (Giacomelli et al., 2020) and 80% (Lechien et al., 2020) of hospitalized patients, with feminine prominence and onset before hospitalization in most cases (Giacomelli et al., 2020; Lechien et al., 2020). Anosmia can be the only clinical manifestation of otherwise asymptomatic and uncomplicated SARS-CoV-2 infection (Gane et al., 2020) and does not seem to relate to disease severity (Moein et al., 2020; Mao et al., 2020). Interestingly, overall prevalence of olfactory complaints seems lower in Asian cohort, with only 10.7% of patients affected by olfactory and taste symptoms (Mao et al., 2020). Viral mutations affecting receptor-binding domain of surface proteins, crucial for viral invasion (Chan et al., 2020), or different ACE2 polymorphisms between Asian and European population (Li et al., 2005), could explain such difference.

Brain imaging has been seldom performed, but in the two reported cases, one patient MRI disclosed bilateral inflammatory obstruction of

the olfactory clefts without any anomaly of the olfactory bulbs or tract volumes (Eliezer et al., 2020) and the other MRI displayed normal signal in the olfactory bulb and tract volumes without signs of nasal congestion (Galougahi et al., 2020).

Direct invasion from SARS-CoV-2 may also induce meningoencephalitis as described in four reports (Moriguchi et al., 2020; Sun and Guan, 2020; Hanna Huang et al., 2020; Al-Olama et al., 2020), all with SARS-CoV-2 Reverse transcriptase-polymerase chain reaction (RT-PCR) positive in the CSF. One patient showed raised intracranial pressure (320 mmH₂O), mild pleocytosis (10 white blood cells per microliter), hyperintense FLAIR signal in right mesial lobe and hippocampus on brain MRI (Moriguchi et al., 2020), another showed no involvement in other organ systems but she experienced symptoms of typical meningeal involvement (fever, headache, lethargy, neck stiffness, photophobia). Lumbar puncture revealed pleocytosis, elevated protein concentration and RT-PCR positive test in CSF as well as in nasopharyngeal swab and a favorable outcome has been reported at day 12 (Hanna Huang et al., 2020). The last case presented with fever, headache and mental status decline later complicated by edema and intracranial hemorrhage (Al-Olama et al., 2020).

Brainstem invasion by SARS-CoV-2 is suspected to contribute to acute respiratory failure through a Ondine curse phenomenon as hinted by the report of a SARS-CoV-2 survivor complaints (Li et al., 2020a): this young patient described the feeling of being compelled to remain awake in order to breathe actively and consciously during the intensive care stay, suggesting central hypopnea respiratory dysfunction. This is a complaint

typical of Ondine curse syndrome that is defined by a respiratory disorder with ineffective breathing, apnoea or respiratory arrest during sleep secondarily to central respiratory generator impairment, as often seen after severe brainstem injury. Two groups of neurons in the brainstem are in particular crucial for rhythmical autonomic respiration: pre-Bötzinger complex (PBC) as primary respiratory oscillator, and the retrotrapezoid nucleus/parafacial respiratory group, as secondary minor respiratory network, participation controlled by PBC. From there, strategically infection and destruction of the PBC region could lead to a shutting down of all breathing generators (Gandhi et al., 2020). Unfortunately, the lack in the reported case of detailed respiratory pattern, blood gas profiles and other eventual signs of brainstem dysfunction do not allow a clear differentiation between pulmonary (low CO₂ levels and raised respiratory rate) and central (low O₂, high CO₂ and reduced respiratory rate) (Turtle, 2020) respiratory failure. However, in previous studies of transgenic mice intranasally infected by SARS-CoV-1 and MERS-CoV, high viral load were found in the brainstem (Netland et al., 2008; Li et al., 2015; McCray et al., 2007) supporting the hypothesis of a central hypopnea contribution to respiratory failure for this novel coronavirus. ACE2 receptor expression in these medullary areas (Doobay et al., 2007) could contribute to brainstem virus invasion and secondarily inflammatory destructive reaction (Netland et al., 2008; McCray et al., 2007).

Three patients with vision impairment, possibly due to direct optic nerve involvement, were also reported without clinical details to better suppose the putative underlying mechanisms (Mao et al., 2020). Even if not demonstrated in human, coronaviruses infections induce optic neuritis in animal models (Seah and Agrawal, 2020).

One case of myelitis (Zhao et al., 2020a) with favorable outcome has been also reported in a SARS-CoV-2 infected patient with symmetrical weakness of lower limbs, tendon reflex reduction, urogenital tracts symptoms and sensory Th10 level. Unfortunately, spinal MRI and CSF analysis to confirm clinical suspicion of myelitis were not performed. The virus direct invasion of spinal cord neurons has been supposed since ACE2 receptors seem to be highly expressed also in that region (Nemoto et al., 2020; Ogata et al., 2019).

Cranial nerves involvement by SARS-CoV-2 infection are also probably responsible of dysgeusia, a symptom present in over 80% of patients and alone, without anosmia, in almost half of cases (Lechien et al., 2020). This symptom is possibly due to the impairment of the gustatory component of facial and glossopharyngeal nerves. The high expression of ACE2 receptors on the tongue epithelium might be responsible for the entrance of the virus in these nerves by the peripheral nervous terminals (Xu et al., 2020) and a subsequent trans-neuronal retrograde pathway may be supposed to hint CNS structures.

Finally, a single case of pure motor third cranial nerve palsy occurring before the respiratory tract symptoms during SARS-CoV-2 infection has been documented (Wei et al., 2020). There, brain MRI excluded aneurysm, cerebrovascular diseases or tumoral lesions and, despite negative SARS-CoV-2 RT-PCR in the CSF, a direct SARS-CoV-2 invasion was proposed as pathological mechanism. Alternatively, inflammatory factors or a microvascular thrombosis due to the hypercoagulable state during the infection are possible alternative mechanisms.

The ACE2 receptors that are critical for SARS-CoV-2 infection of respiratory tracts could play an important role in brain invasion, as ACE2 receptors are highly expressed in the CNS vessels offering to SARS-CoV-2 a mean to cross blood barriers (Hamming et al., 2004). However, only one human brain pathological study is currently available (Paniz-Mondolfi et al., 2020) that supports a direct brain invasion by SARS-CoV-2 infection, showing virus particles within cytoplasmic vacuoles in brain capillary endothelial cells of frontal lobe confirmed by RT-PCR on frozen tissue targeting 4 different regions of the viral genome. Even if evidences are scarcer than for previous coronavirus studies (Oshiro et al., 1971), where viral particles were demonstrated within cytoplasm vesicles in the neuron cell body, they at least plead for a hematogenous route invasion. This hypothesis is also supported by a post-mortem brain MRI study of 20 patients who died from severe

SARS-CoV-2 infection where four of them showed patterns of acute intracranial vasculopathy that could relate both to endothelitis triggered by direct SARS-CoV-2 invasion and systemic inflammatory syndrome (Coolen et al., 2020).

2. Indirect involvement of the nervous system in SARS-CoV-2 associated to innate immunity (over-) activation

Some neurological manifestations seen in SARS-CoV-2 can be attributed to an indirect involvement of CNS secondary to cardiopulmonary insult or the virus infection related systemic inflammation/sepsis due to the innate immunity activation. Among them, severe cases of stroke and epilepsy reported during SARS-CoV-2 infection likely relate to these mechanisms.

The prevalence of stroke during SARS-CoV-2 amounts to 6% (Li et al., 2020b) and the link between those two conditions is suggested by shared risk factors and the relationship between SARS-CoV-2 severity and stroke occurrence. Indeed, patients with risk factors for SARS-CoV-2 severe infection may have an increased risk of stroke and mortality due to several complications such as hypotension, shock, arrhythmogenic cardiopathy, heart failure, disseminated intravascular coagulation. Cerebrovascular complications in hospitalized patients presented generally later in SARS-CoV-2 illness course (median 10 days). However, stroke has also been reported as presenting manifestation of SARS-CoV-2 infection, as described in three of the four patients reported in one case series (Avula et al., 2020), in two of six from Mao et al. (2020) and in six of nine in an Italian series (Lodigiani et al., 2020). More recent cases series (Oxley et al., 2020; Beyrouiti et al., 2020; Avula et al., 2020) showed high NIH stroke scale (NIHSS) score at onset, high frequency of large vessel occlusion and perturbed biological profile with elevated inflammatory markers or coagulopathy in the affected patients.

Cerebrovascular complications could be indirectly related to SARS-CoV-2 through cardiopulmonary insult, as seen for any other respiratory infection (Elkind, 2007), but the more likely mechanism is probably through an hypercoagulation state, termed sepsis-induced coagulopathy (SIC), now a well-defined entity occurring during SARS-CoV-2 course (Tang et al., 2020). Indeed, a third of all SARS-CoV-2 patients presents with thrombotic complication despite adequate thromboprophylaxis (Klok et al., 2020) and, elevated biological inflammatory markers (white blood cells, neutrophil count, C-reaction protein and D-dimers levels), known to favour thrombo-embolic diseases in general, have been reported as in the previous epidemic of SARS-CoV-1 infection (Umaphathi et al., 2004). Furthermore, the release by immune effector cells of large amounts of pro-inflammatory cytokines (IFN α , IFN γ , IL-1 β , IL-6, IL-12, etc.), a phenomenon dubbed the “cytokine storm” in severe SARS-CoV-2 systemic inflammatory syndrome (Mehta et al., 2020; Coperchini et al., 2020) may further contribute to an endothelial dysfunction and micro-thrombosis. Indeed, interleukin (IL)-6 that correlates with the severity of SARS-CoV-2 infection symptoms (Zhou et al., 2020) is a known risk factor for stroke (Jenny et al., 2019) and anti-inflammatory therapy targeting IL-1 β , secreted by the innate immune system, protects from stroke recurrences (Ridker et al., 2017). Finally, innate immune response targeting endothelial cells infected by SARS-CoV-2 through the ACE2 receptor could lead to an endothelitis that could trigger or enhance those thrombo-embolic complications. This explains the high stroke recurrence and venous thrombosis among these patients (Beyrouiti et al., 2020).

Another mechanism for SARS-CoV-2 virus to induce thrombosis and organ injury is dysregulation of ACE/angiotensin (AT) axis. Surface S-protein, binding ACE2 receptors with a strong affinity (Zou et al., 2020) may downregulate ACE2 receptors and AT2 receptor pathway. Resultant effect of unbalanced overactivation of AT1 receptors way and inhibition of AT2 receptors induce vascular permeability and acute organ injury (Iroegbu et al., 2020). Brain capillary endothelium may be exposed to this altered balance between pro- and anti-inflammatory pathways resulting in increment of permeability or even direct loss of integrity and

subsequent alteration of cerebral blood flow autoregulation and increased risk of cerebral hemorrhage or ischemia (Sharifi-Razavi et al., 2020), a mechanism thought to contribute to the acute intracranial vasculopathy post-mortem MRI anomalies found in four out of 20 decedents from severe SARS-CoV-2 infection (Coolen et al., 2020).

SARS-CoV-2 related sepsis could explain a reported case of aneurysmal rupture (Muhammad et al., 2020). Systemic inflammation with T helper 1 response associated to innate immunity have been already reported as favouring factors to wall intracranial aneurysm instability, as macrophages and inflammatory factors have been found in the wall of ruptured intracranial aneurysms (Zhang et al., 2016).

Septic state and related inflammatory cytokines also favours acute seizures (Oddo et al., 2009) and likely explain the two cases of seizures reported during SARS-CoV-2 infection: one from a Chinese case series (Mao et al., 2020), without EEG data who presented with clinical features of motor manifestations and loss of consciousness compatible with seizure; a second case (Balloy et al., 2020) reported at day 15 of hypoxic pneumonia with alteration of consciousness correlated to EEG abnormalities compatible with seizure. To note, in this latter case, the patient had no history of seizures, no toxic blood concentration of drugs, unremarkable CSF analysis with negative RT-PCR SARS-CoV-2 test and no structural abnormalities in MRI. However, many seizures may have gone unnoticed due to lack of systematic EEG monitoring. For instance, in Mao's series of 16 patients presented with confusion as presenting symptom in half of cases or in the case series (Lu et al., 2020) of 306 mild to moderate ill patients missed to find any clinical seizure or status epilepticus, despite the co-occurrence of some potentially trigger conditions (acute cerebrovascular disease, hypoxia, antibiotic drug, systemic disease, sepsis, etc). Indeed, confusion and sepsis are both associated to up to 25% of non-convulsive seizures when specifically sought with EEG studies (Oddo et al., 2009).

For this group of patients, management should include adequate thromboprophylaxis as well as anti-inflammatory drugs targeting innate immune system (Divani et al., 2020). This strategy could possibly result in a restored homeostasis and decreased number of inflammation-related neurological complications.

3. Post-infectious neurological syndromes (PINS)

Post-infectious neurological syndromes (PINS) (Marchioni et al., 2013) can occur in SARS-CoV-2 infection like in any infectious epidemic, see for instance Guillain-Barré syndrome (GBS) reports in the recent Zika virus infection (Parra et al., 2016). PINS can involve both peripheral and central nervous systems, separately or in combination, and follow infection onset by a median number of six days, with 90% of PINS occurring within three weeks after the infection onset (Marchioni et al., 2013). The putative underlying mechanisms of PINS may include the inflammatory state during SARS-CoV-2 infection which can favour an aberrant immune response against nervous system due to both cell-mediated immune reaction and involvement of the humoral immune system resulting in the expansion of host antibodies or lymphocytes cross-reactive with both viral and self-antigens ("molecular mimicry") (Fairweather et al., 2005; Rose, 2017). Indeed, in patients with SARS, autoantibodies against the coronavirus spike protein were found to react against human epithelial and endothelial cells with consequent cytotoxicity (Yang et al., 2005). Similarly, in patients with SARS-CoV-2 infection, antibodies against the virus can also attack antigens of human endothelial cells in cerebral vessels or directly neurons through the BBB disrupted.

To date, peripheral PINS associated to SARS-CoV-2 infection consist in reports of a classic GBS in a total of 13 patients (Zhao et al., 2020b; Padroni et al., 2020; Coen et al., 2020; Sedaghat and Karimi, 2020; Virani et al., 2020; Toscano et al., 2020; Alberti et al., 2020; Otmani et al., 2020; Camdessanche et al., 2020) and two reports of patients with Miller Fisher's triad of ophthalmoparesis, ataxia and areflexia with as only specific feature in both cases of SARS-CoV-2 related symptoms of anosmia

and ageusia (Gutiérrez-Ortiz et al., 2020). Interestingly, in these cases, pulmonary involvement was very mild and RT-PCR for SARS-CoV-2 in CSF negative, providing support to an aberrant immune response more than a direct viral invasion as underlying mechanism.

A probable central PINS is represented by a case of acute hemorrhagic necrotizing encephalopathy (AHNE) or Weston-Hurst syndrome (Poyiadji et al., 2019) presenting as an altered mental status after a three-day history of cough and fever in a 60-year otherwise healthy woman positive for SARS-CoV-2 viral nucleic acid in the nasopharyngeal swab. Brain MRI showed bilateral thalamic and medial temporal lobe FLAIR hyperintensities, hemorrhages on susceptibility-weighted images and postcontrast rim enhancement. Weston-Hurst syndrome is a dramatic form of central PINS, more frequent in childhood, due to a breakdown of the BBB with a cytokine storm release.

Another case of probable central PINS has been described in another report (Zanin et al., 2020) of newly diagnosed demyelinating lesions in brain and spinal cord appeared few days after anosmia and dysgeusia, followed by overt pneumonia and positive nasopharyngeal swab test. Work-up revealed negative RT-PCR for SARS-CoV-2 in CSF and absence of intrathecal oligoclonal antibody production. According to the author hypothesis, CNS damage appears due to a post-infectious response since brain lesions were not present in previous follow-up imaging for an intracranial aneurysm.

Three reports of autoimmune encephalitis have been afterwards reported. In the first series (Bernard-Valnet et al., 2020), two patients with mild respiratory and general symptoms developed confusion and alteration of mental state, with evidence of status epilepticus in one of the two patients. Both had abnormal lumbar puncture with pleocytosis and elevation of proteins, but negative RT-PCR for SARS-CoV-2 and normal brain MRI. The second case series (Dogan et al., 2020) reported six critically ill patients with confusion and agitation. Brain MRI performed in a half of patients showed cortical and/or white matter hyperintensities, with contrast enhancement and sulcal hemorrhagic features. Lumbar puncture was RT-PCR SARS-CoV-2 negative without pleocytosis but showed elevation of proteins. Patients demonstrated dramatic benefit from plasmapheresis except for one case. That, combined with negative RT-PCR and reversible MRI findings following plasmapheresis, pointed out an autoimmune-mediated involvement. A third case of parainfectious encephalitis was described (Pilotto et al., 2020) in a patient affected by progressive and severe alteration of consciousness without respiratory symptoms. Lumbar puncture showed mild pleocytosis, elevation of proteins and negative RT-PCR for SARS-CoV-2. Brain MRI was normal and EEG only generalized slowed. Methylprednisolone 1g/day for 5 days was started with clinical improvement evident since first day. Patient was discharged with unremarkable neurological examination and progressive tapering oral corticotherapy.

Finally, the severe hypopnea observed in SARS-CoV-2 patients could partly result from the combination of a direct neuroinvasion as described above and PINS leading to central hypoventilation. The timing of this respiratory degradation, typically around day 10, could argue to a neurological involvement due to PINS.

Noteworthy, these post-infectious cases shared mild or minimal pulmonary involvement, delayed neurological symptoms after virus infection and response to immune therapy. These considerations could be important for early detection of these manifestations, prompt therapy and prognosis.

4. Neurological-like symptoms

SARS-CoV-2 generally begins as a flu-like syndrome explaining the high prevalence of headache, myalgia and dizziness that likely reflect systemic inflammation more than a direct neurological involvement, as their frequency correlates with the severity of the pulmonary involvement (Heydari et al., 2020). As shown in observational studies published during first weeks after the spread of the pandemic (Wang et al., 2020; Huang et al., 2020; Zhou et al., 2020; Chen et al., 2020), the most

frequent neurological-like symptoms were myalgia (11–44%), followed by fatigue (23–69.9%) and headache (6.5–8%). Heterogeneity in symptom reporting methods and number of studies searching these manifestations from each study must be considered.

5. Neurological complications in other Coronavirus respiratory infections

To anticipate potential other neurological manifestations from SARS-CoV-2 infection, it is useful to look back at the neurological complications previously seen in adults infected by other human CoVs, such as SARS-CoV-1 and MERS.

In SARS-CoV-1 patients, the most frequent neurological manifestations reported were neuromuscular disorders (Zochodne, 2004; Tsai et al., 2004, 2005), explained by a direct virus invasion and indirect mechanisms relating to aberrant systemic inflammatory response and to drugs used in ICU settings that led to axonal polyneuropathy, myopathy and rhabdomyolysis. Similar phenomena are likely to be shared by SARS-CoV-2 and should be closely looked upon in the coming weeks. Neurological complications reported during MERS infection are less abundant, probably due to high mortality (about 35%) for this virus (WHO. World Health Organization, 2016). However, in the largest series of MERS infected patients, more than one quarter of patients had confusion and 8.6% seizures suggesting brain hemispheric impairments arguing further for human coronavirus potential neurotropism (Saad et al., 2014).

5.1. Limitations

Scientific reports centered on neurological involvement in SARS-CoV-2 are still scarce and risk of publication bias is high. Moreover, most of the studies come from hospitals in a period of overloaded work and healthcare crisis and from cohorts with highly different outcomes. The high rate of mortality in Italian cohorts could possibly lead to an underestimation of subtle neurological symptoms. Neither, a standard evaluation of neurological patients was used in all those reports.

Retrospective and prospective studies of larger cohorts are necessary to assess correctly nervous system involvement.

6. Conclusion

In conclusion, there are evidences for a neurological involvement in patients affected by SARS-CoV-2. Yet, neurological symptoms are mostly mild and consist of hypo/anosmia and dys/ageusia through potentially direct viral invasion, while severe neurological patterns are rare and likely due to indirect pathogenic mechanisms like systemic inflammation and post-infectious autoimmune mechanism.

Funding

NA.

Ethics approval (include appropriate approvals or waivers)

NA.

Authors' contributions according to CRediT

Pasquale Scoppettuolo: Design and conceptualized study; literature review and data collection; analyzed the data; drafted the manuscript for intellectual contents; submission.

Serena Borrelli: Literature review and data collection; analyzed the data; drafting and revision.

Gilles Naeije: Overall supervision; analyzed the data; drafting and revision.

Declaration of competing interest

None.

Appendix A. Supplementary data

Supplementary data to this article can be found online at <https://doi.org/10.1016/j.bbih.2020.100094>.

References

- Al-Olama, M., Rashid, A., Garozzo, D., 2020. COVID-19-associated meningoencephalitis complicated with intracranial hemorrhage: a case report [Internet] *Acta Neurochir (Wien)*. Available from: <http://www.ncbi.nlm.nih.gov/pubmed/32430637>.
- Alberti, P., Beretta, S., Piatti, M., Karantzoulis, A., Piatti, M.L., Santoro, P., et al., 2020. Guillain-Barré syndrome related to COVID-19 infection [Internet] *Neurol - Neuroimmunol Neuroinflammation* 7 (4), e741. Available from: <http://nn.neurology.org/lookup/doi/10.1212/NXI.0000000000000741>.
- Avula, A., Nalleballe, K., Narula, N., Sapozhnikov, S., Dandu, V., Toom, S., et al., 2020. COVID-19 presenting as stroke [Internet] *Brain Behav. Immun.* <https://doi.org/10.1016/j.bbi.2020.04.077> (April):0–1. Available from.
- Balloy, G., Mahé, P., Leclair-Visonneau, L., Péron, Y., Derkinderen, P., Magot, A., et al., 2020. Non-lesional status epilepticus in a patient with coronavirus disease 2019 [Internet] *Clin. Neurophysiol.* (January). Available from <http://www.ncbi.nlm.nih.gov/pubmed/32389697>.
- Bernard-Valnet, R., Pizzarotti, B., Anichini, A., Demars, Y., Russo, E., Schmidhauser, M., et al., 2020. Two patients with acute meningo-encephalitis concomitant to SARS-CoV-2 infection [Internet] *medRxiv*, 2020.04.17.20060251. Available from: <http://medrxiv.org/content/early/2020/04/21/2020.04.17.20060251.abstract>.
- Beyroufi, R., Adams, M.E., Benjamin, L., Cohen, H., Farmer, S.F., Goh, Y.Y., et al., 2020. Characteristics of ischaemic stroke associated with COVID-19 [Internet] *J. Neurol. Neurosurg. Psychiatry*, 0(0):jnnp-2020-323586. Available from: <http://jnnp.bmj.com/lookup/doi/10.1136/jnnp-2020-323586>.
- Bohmwald, K., Gálvez, N.M.S., Ríos, M., Kalergis, A.M., 2018. Neurologic alterations due to respiratory virus infections. *Front. Cell. Neurosci.* 12 (October), 1–15.
- Camdessanche, J.P., Morel, J., Pozzetto, B., Paul, S., Tholance, Y., Botelho-Nevers, E., 2020. COVID-19 may induce Guillain-Barré syndrome. *Paris Rev. Neurol.* (January).
- Chan, J.F.-W., Yuan, S., Kok, K., Kai-Wang To, K., Chu, H., Yang, J., et al., 2020. A familial cluster of pneumonia associated with the 2019 novel coronavirus indicating person-to-person transmission: a study of a family cluster. *Lancet* 395 (January), 19–21.
- Chen, N., Zhou, M., Dong, X., Qu, J., Gong, F., Han, Y., et al., 2020. Epidemiological and clinical characteristics of 99 cases of 2019 novel coronavirus pneumonia in Wuhan, China: a descriptive study [Internet] *Lancet* 395 (10223), 507–513. [https://doi.org/10.1016/S0140-6736\(20\)30211-7](https://doi.org/10.1016/S0140-6736(20)30211-7). Available from.
- Coen, M., Jeanson, G., Culebras Almeida, A., Hübers, A., Stierlin, F., Najjar, I., et al., 2020. Guillain-Barré syndrome as a complication of SARS-CoV-2 infection *A. Brain Behav. Immun.*
- Coolen, T., Lolli, V., Sadeghi, N., Rovai, A., Trotta, N., Taccone, F.S., et al., 2020 Jan 1. Early postmortem brain MRI findings in COVID-19 non-survivors [Internet] *medRxiv*, 2020.05.04.20090316. Available from: <http://medrxiv.org/content/early/2020/05/08/2020.05.04.20090316.abstract>.
- Coperchini, F., Chiovato, L., Croce, L., Magri, F., Rotondi, M., 2020. Cytokine and Growth Factor Reviews the cytokine storm in COVID-19 : an overview of the involvement of the chemokine/chemokine-receptor system [Internet] *Cytokine Growth Factor Rev.* <https://doi.org/10.1016/j.cytogfr.2020.05.003> (May):1–8. Available from.
- Desforges, M., Le Coupance, A., Dubeau, P., Bourgoignie, A., Lajoie, L., Dubé, M., et al., 2019. Human coronaviruses and other respiratory viruses: underestimated opportunistic pathogens of the central nervous system? *Viruses* 12 (1), 1–28.
- Ding, Y., Wang, H., Shen, H., Li, Z., Geng, J., Han, H., et al., 2003. The clinical pathology of severe acute respiratory syndrome (SARS): a report from China. *J. Pathol.* 200 (3), 282–289.
- Divani, A., Andalib, S., Di Napoli, M., Lattanzi, S., Hussain, M., Biller, J., et al., 2020. Coronavirus disease 2019 and stroke: clinical manifestations and pathophysiological insights. *J. Stroke Cerebrovasc. Dis.* May.
- Dogan, L., Kaya, D., Sarikaya, T., Zengin, R., Dincer, A., Ozkan Akinci, I., et al., 2020. Plasmapheresis treatment in COVID-19-related autoimmune meningoencephalitis: case series [Internet] *Brain Behav. Immun.* (January). Available from <http://www.ncbi.nlm.nih.gov/pubmed/32389697>.
- Doobay, M., Talman, L., Obr, T., Tian, X., Davison, R., Lazartigues, E., 2007. Differential expression of neuronal ACE2 in transgenic mice with overexpression of the brain renin-angiotensin system [Internet] *Am. J. Physiol. Regul. Integr. Comp. Physiol.* 292 (1), R373–R381. Available from: <https://www.ncbi.nlm.nih.gov/pmc/articles/PMC3624763/pdf/nihms412728.pdf>.
- Eliezer, M., Hautefort, C., Hamel, A., Verillaud, B., Herman, P., Houdart E., Eloit, C., 2020. Sudden and complete olfactory loss function as a possible symptom of COVID-19. *JAMA Otolaryngol Neck Surg.*
- Elkind, M.S.V., 2007. Why now? Moving from stroke risk factors to stroke triggers. *Curr. Opin. Neurol.* 20 (1), 51–57.
- Fairweather, D.L., Frisancho-Kiss, S., Rose, N.R., 2005. Viruses as adjuvants for autoimmunity: evidence from Coxsackievirus-induced myocarditis. *Rev. Med. Virol.* 15 (1), 17–27.

- Galougahi, M., Ghorbani, J., Bakshshayeshkaram, M., Naeini, S., Haseli, S., 2020. Olfactory bulb magneti resonance imaging in SARS-CoV-2 induced anosmia: the first report. *Acad. Radiol.* 1–2.
- Gandhi, S., Srivastava, A., Ray, U., Tripathi, P., 2020. Does collapse of respiratory center in the brain responsible for breakdown of COVID-19 patients? [Internet] *ACS Chem. Neurosci.* aacschemneuro.0c00217. Available from <https://pubs.acs.org/doi/10.1021/acschemneuro.0c00217>.
- Gane, S., Kelly, C., Hopkins, C., 2020. Isolated sudden onset anosmia in COVID-19 infection. A novel syndrome? *Rhinology.* April.
- Giacomelli, A., Pezzati, L., Conti, F., Bernacchia, D., Siano, M., Oreni, L., et al., 2020. Self-reported olfactory and taste disorders in SARS-CoV-2 patients: a cross-sectional study. *Clin. Infect. Dis.* (Xx Xxxx), 2–3.
- Goldberg, M.F., Goldberg, M.F., 2020. Cerebrovascular Disease in COVID-19, vols. 1–3.
- Gronseth, G., Cox, J., Gloss, D., Marillat, S., Dittman, J., Armstrong, M., et al., 2017. edition: clinical practice guideline process manual. *Am Acad Neurol* 1–76, 2017.
- Gutiérrez-Ortiz, C., Méndez, A., Rodrigo-Rey, S., San Pedro-Murillo, E., Bermejo-Guerrero, L., Gordo-Mañas, R., et al., 2020. Miller Fisher Syndrome and polyneuritis cranialis in COVID-19 [Internet] *Neurology* 241. Available from <http://www.ncbi.nlm.nih.gov/pubmed/32303650>.
- Hamming, L., Timens, W., Bulthuis, M.L.C., Lely, A.T., Navis, G.J., van Goor, H., 2004. Tissue distribution of ACE2 protein, the functional receptor for SARS coronavirus. A first step in understanding SARS pathogenesis. *J. Pathol.* 203 (2), 631–637.
- Hanna Huang, Y., Jiang, D., Huang, J.T., 2020. A case of COVID-19 encephalitis [Internet] *Brain Behav. Immun.* (January). Available from <http://www.ncbi.nlm.nih.gov/pubmed/32387508>.
- Helms, J., Kremer, S., Merdji, H., Clere-Jehl, R., Schenck, M., Kummerlen, C., et al., 2020. Neurologic features in severe SARS-CoV-2 infection [Internet] *N. Engl. J. Med.* 1–2. Available from <http://www.ncbi.nlm.nih.gov/pubmed/32294339>.
- Heydari, K., Rismantab, S., Shamsirian, A., Lotfi, P., Shadmehri, N., 2020. Clinical and Paraclinical Characteristics of COVID-19 patients : a systematic review and meta-analysis. *medRxiv* 1–39.
- Huang, C., Wang, Y., Li, X., Ren, L., Zhao, J., Hu, Y., et al., 2020. Clinical features of patients infected with 2019 novel coronavirus in Wuhan, China. *Lancet* 395 (10223), 497–506.
- Hung, E., Chim, S., Chan, P., Tong, Y., Ng, E., Chiu, R., et al., 2003. Detection of SARS coronavirus RNA in the cerebrospinal fluid of a patient with severe acute respiratory syndrome. *Clin. Chem.* 49 (12), 2107–2108.
- Iroegbu, J.D., Ifenatuoha, C.W., Ijomone, O.M., 2020. Potential Neurological Impact of Coronaviruses : Implications for the Novel SARS-CoV-2 (April).
- Jenny, N.S., Callas, P.W., Judd, S.E., McClure, L.A., Kissela, B., Zakai, N.A., et al., 2019. Inflammatory cytokines and ischemic stroke risk: the REGARDS cohort. *Neurology* 92 (20), E2375–E2384.
- Klok, F.A., Kruip, M.J.H.A., van der Meer, N.J.M., Arbous, M.S., Gommers, D.A.M.P.J., Kant, K.M., et al., 2020. Incidence of thrombotic complications in critically ill ICU patients with COVID-19 [Internet] *Thromb. Res.* (xxxx):1–3. Available from <http://www.ncbi.nlm.nih.gov/pubmed/32291094>.
- Lau, K., Yu, W., Chu, C., Lau, S., Sheng, B., 2004. Possible centrale nervous system infection by SARS Coronavirus, 10 (2), 2–4.
- Lechien, J.R., Chiesa-Estomba, C.M., De Statti, D.R., Horoi, M., Le Bon, S.D., Rodriguez, A., et al., 2020. Olfactory and gustatory dysfunctions as a clinical presentation of mild-to-moderate forms of the coronavirus disease (COVID-19): a multicenter European study [Internet] *Eur Arch Otorhinolaryngol* 2 (0123456789). Available from <http://www.ncbi.nlm.nih.gov/pubmed/32253535>.
- Li, W., Zhang, C., Sui, J., Kuhn, J.H., Moore, M.J., Luo, S., et al., 2005. Receptor and viral determinants of SARS-coronavirus adaptation to human ACE2. *EMBO J.* 24 (8), 1634–1643.
- Li, K., Wohlford-Lenane, C., Perlman, S., Zhao, J., Jewell, A.K., Reznikov, L.R., et al., 2015. Middle east respiratory syndrome coronavirus causes multiple organ damage and lethal disease in mice transgenic for human dipeptidyl peptidase 4. *J. Infect. Dis.* 212 (11), 712–722.
- Li, Y.C., Bai, W.Z., Hashikawa, T., 2020. The neuroinvasive potential of SARS-CoV2 may be at least partially responsible for the respiratory failure of COVID-19 patients. *J. Med. Virol.* 2, 0–2.
- Li, Y., Wang, M., Zhou, Y., Chang, J., Xian, Y., Mao, L., et al., 2020. Acute cerebrovascular disease following COVID-19: a single center, retrospective, observational study [Internet] *SSRN Electron J* 19. Available from <https://www.ssrn.com/abstract=3550025>.
- Lodigiani, C., Iapichino, G., Carenzo, L., Cecconi, M., Ferrazzi, P., Teresa, M., et al., 2020. Venous and arterial thromboembolic complications in COVID-19 patients admitted to an academic hospital in Milan , Italy. *Thromb. Res.* (January), 9–14.
- Lu, L., Xiong, W., Liu, D., Liu, J., Yang, D., Li, N., et al., 2020. New-onset acute symptomatic seizure and risk factors in corona virus disease 2019: a retrospective multicenter study. *Epilepsia* (April), 1–5.
- Mao, L., Wang, M., Chen, S., He, Q., Chang, J., Hong, C., et al., 2020. Neurological manifestations of hospitalized patients with COVID-19 in wuhan, China: a retrospective case series study. *medRxiv* 2020, 02.22.20026500.
- Marchioni, E., Ravaglia, S., Montomoli, C., Tavazzi, E., Minoli, L., Baldanti, F., et al., 2013. Postinfectious neurologic syndromes: a prospective cohort study. *Neurology* 80 (10), 882–889.
- McCray, P.B., Pewe, L., Wohlford-Lenane, C., Hickey, M., Manzel, L., Shi, L., et al., 2007. Lethal infection of K18-hACE2 mice infected with severe acute respiratory syndrome coronavirus. *J. Virol.* 81 (2), 813–821.
- Mehta, P., McAuley, D.F., Brown, M., Sanchez, E., Tattersall, R.S., Manson, J.J., 2020. COVID-19: consider cytokine storm syndromes and immunosuppression [Internet] *Lancet* 395 (10229). [https://doi.org/10.1016/S0140-6736\(20\)30628-0](https://doi.org/10.1016/S0140-6736(20)30628-0), 1033–4. Available from.
- Moein, S.T., Hashemian, S.M.R., Mansourafshar, B., Khorram-Tousi, A., Tabarsi, P., Doty, R.L., 2020. Smell dysfunction: a biomarker for COVID-19 [Internet] *Int Forum Allergy Rhinol.* Available from <http://www.ncbi.nlm.nih.gov/pubmed/32301284>.
- Moher, D., Liberati, A., Tetzlaff, J., Altman, D.G., Altman, D., Antes, G., et al., 2009. Preferred reporting items for systematic reviews and meta-analyses: the PRISMA statement. *PLoS Med.* 6 (7).
- Moriguchi, T., Harii, N., Goto, J., Harada, D., Sugawara, H., Takamino, J., et al., 2020. A first Case of Meningitis/Encephalitis associated with SARS-Coronavirus-2 [Internet] *Int. J. Infect. Dis.* (March). Available from <http://www.ncbi.nlm.nih.gov/pubmed/32251791>.
- Muhammad, S., Petridisa, A., Cornelius, J.F., 2020. Severe brain haemorrhage and concomitant COVID-19 Infection: a neurovascular complication of COVID-19 Sajjad. *Brain Behav. Immun.* S0889-1591(May).
- Nath, A., 2020. Neurologic complications of coronavirus infections [Internet] *Neurology.* <https://doi.org/10.1212/WNL.00000000000009455>. Available from <http://www.neurology.org/lookup/doi/10.1212/WNL.00000000000009455>.
- Nemoto, W., Yamagata, R., Nakagawasai, O., Nakagawa, K., Hung, W.Y., Fujita, M., et al., 2020. Effect of spinal angiotensin-converting enzyme 2 activation on the formalin-induced nociceptive response in mice [Internet] *Eur. J. Pharmacol.* 872. <https://doi.org/10.1016/j.ejphar.2020.172950> (July 2019):172950. Available from.
- Netland, J., Meyerholz, D.K., Moore, S., Cassell, M., Perlman, S., 2008. Severe acute respiratory syndrome coronavirus infection causes neuronal death in the absence of encephalitis in mice transgenic for human ACE2. *J. Virol.* 82 (15), 7264–7275.
- Oddo, M., Carrera, E., Claassen, J., Mayer, S.A., Hirsch, L.J., 2009 Jun. Continuous electroencephalography in the medical intensive care unit [Internet] *Crit. Care Med.* 37 (6), 2051–2056. <https://doi.org/10.1097/CCM.0b013e3181a00604>. Available from.
- Ogata, Y., Nemoto, W., Yamagata, R., Nakagawasai, O., Shimoyama, S., Furukawa, T., et al., 2019. Anti-hypersensitive effect of angiotensin (1-7) on streptozotocin-induced diabetic neuropathic pain in mice. *Eur. J. Pain* 23 (4), 739–749.
- Ollarves-Carrero, M.F., Rodríguez-Morales, A.G., Bonilla-Aldana, D.K., Rodríguez-Morales, A.J., 2020. Anosmia in a Healthcare Worker with COVID-19 in Madrid, Spain [Internet]. *Travel Med Infect Dis* (April):101666. Available from <http://www.ncbi.nlm.nih.gov/pubmed/32298782>.
- Oshiro, L.S., Schieble, J.H., Lennette, E.H., 1971. Electron microscopic studies of coronavirus. *J. Gen. Virol.* 12 (2), 161–168.
- Otmani, H. El, Moutawakil, B. El, Rafai, M.-A., Benna, N. El, Kettani, C. El, Soussi, M., et al., 2020. Covid-19 and Guillain-Barré Syndrome: More than a Coincidence! *Rev Neurol. Paris* (January).
- Oxley, T., Mocco, J., Majidi, S., Kellner, C., Shoirah, H., Singh, I., et al., 2020. Large-vessel stroke as a presenting feature of covid-19 in the young. *N. Engl. J. Med.* 382 (20) e60(1)-e60(3).
- Padroni, M., Mastrangelo, V., Asioli, G.M., Pavolucci, L., Abu-Rumeileh, S., Piscaglia, M.G., et al., 2020. Guillain-Barré syndrome following COVID-19: new infection, old complication? [Internet] *J. Neurol.* <https://doi.org/10.1007/s00415-020-09849-6> (Table 1):1–3. Available from.
- Paniz-Mondolfi, A., Bryce, C., Grimes, Z., Gordon, R.E., Reidy, J., Lednicky, J., et al., 2020. Central nervous system involvement by severe acute respiratory syndrome coronavirus-2 (SARS-CoV-2). *J. Med. Virol.* 2, 0–3.
- Parra, B., Lizarazo, J., Jiménez-Arango, J.A., Zea-Verá, A.F., González-Manrique, G., Vargas, J., et al., 2016. Guillain-Barré syndrome associated with Zika virus infection in Colombia. *N. Engl. J. Med.* 375 (16), 1513–1523.
- Pilotto, A., Odolini, S., Stefano Masciocchi, S., Comelli, A., Volonghi, I., Gazzina, S., et al., 2020. Steroid-responsive encephalitis in COVID-19 disease [Internet] *Ann. Neurol.* Available from <http://www.ncbi.nlm.nih.gov/pubmed/32418288>.
- Poyiadji, N., Shahin, G., Noujaim, D., Stone, M., Patel, S., Griffith, B., 2019. COVID-19-associated acute hemorrhagic necrotizing encephalopathy: CT and MRI features. *Radiology* 2, 1–5.
- Ridker, P.M., Everett, B.M., Thuren, T., MacFadyen, J.G., Chang, W.H., Ballantyne, C., et al., 2017. Antiinflammatory therapy with canakinumab for atherosclerotic disease. *N. Engl. J. Med.* 377 (12), 1119–1131.
- Rose, N.R., 2017. Negative selection, epitope mimicry and autoimmunity [Internet] *Curr. Opin. Immunol.* 49, 51–55. <https://doi.org/10.1016/j.coi.2017.08.014>. Available from.
- Rothe, C., Schunk, M., Sothmann, P., Bretzel, G., Froeschl, G., Wallrauch, C., et al., 2020. Transmission of 2019-NCOV infection from an asymptomatic contact in Germany. *N. Engl. J. Med.* 382 (10), 970–971.
- Saad, M., Omrani, A.S., Baig, K., Bahloul, A., Elzein, F., Matin, M.A., et al., 2014. Clinical aspects and outcomes of 70 patients with Middle East respiratory syndrome coronavirus infection: a single-center experience in Saudi Arabia. *Int. J. Infect. Dis.* 29 (January), 301–306.
- Seah, I., Agrawal, R., 2020. Can the coronavirus disease 2019 (COVID-19) affect the eyes? A review of coronaviruses and ocular implications in humans and animals [Internet] *Ocul. Immunol. Inflamm.* 28 (3), 391–395. <https://doi.org/10.1080/09273948.2020.1738501>. Available from.
- Sedaghat, Z., Karimi, N., 2020. Guillain Barre syndrome associated with COVID-19 infection: a case report [Internet] *J Clin Neurosci* (xxxx). <https://doi.org/10.1016/j.jocn.2020.04.062>, 10–2. Available from.
- Sharif-Razavi, A., Karimi, N., Rouhani, N., 2020. COVID 19 and intra cerebral hemorrhage: causative or coincidental [Internet] *New Microbes New Infect.* <https://doi.org/10.1016/j.nmni.2020.100669>, 100669. Available from.
- St-Jean, J.R., Jacomy, H., Desforges, M., Vabret, A., Freymuth, F., Talbot, P.J., 2004. Human respiratory coronavirus OC43: genetic stability and neuroinvasion. *J. Virol.* 78 (16), 8824–8834.
- Sun, T., Guan, J., 2020. Novel coronavirus and central nervous system [Internet] *Eur. J. Neurol.* <https://doi.org/10.1111/ene.14227>, n/a(n/a). Available from.

- Talan, J., 2020. COVID-19: neurologists in Italy to colleagues in US: look for poorly-defined neurologic conditions in patients with the coronavirus [Internet] *Neurol. Today*. Available from: <https://journals.lww.com/neurotodayonline/blog/breakingnews/pages/post.aspx?PostID=920>.
- Tang, N., Bai, H., Chen, X., Gong, J., Li, D., Sun, Z., 2020. Anticoagulant treatment is associated with decreased mortality in severe coronavirus disease 2019 patients with coagulopathy. *J. Thromb. Haemostasis* (March), 1094–1099.
- Toscano, G., Palmerini, F., Ravaglia, S., Ruiz, L., Invernizzi, P., Cuzzoni, M., et al., 2020. Guillain-barré syndrome associated with SARS-CoV-2. *N. Engl. J. Med.* 4–6.
- Tsai, L.K., Hsieh, S.T., Chao, C.C., Chen, Y.C., Lin, Y.H., Chang, S.C., et al., 2004. Neuromuscular disorders in severe acute respiratory syndrome. *Arch. Neurol.* 61 (11), 1669–1673.
- Tsai, L.K., Hsieh, S.T., Chang, Y.C., 2005. Neurological manifestations in severe acute respiratory syndrome. *Acta Neurol. Taiwan* 14 (3), 113–119.
- Turtle, L., 2020. Respiratory failure alone does not suggest central nervous system invasion by SARS-CoV-2. *J. Med. Virol.* 0–2. <https://doi.org/10.1002/jmv.25828>.
- Umapathi, T., Kor, A.C., Venketasubramanian, N., Lim, C.C.T., Pang, B.C., Yeo, T.T., et al., 2004. Large artery ischaemic stroke in severe acute respiratory syndrome (SARS). *J. Neurol.* 251 (10), 1227–1231.
- Virani, A., Rabold, E., Hanson, T., Haag, A., Elrufay, R., Cheema, T., et al., 2020. Guillain-Barré Syndrome associated with SARS-CoV-2 infection. *IDCases* [Internet] 20, e00771. <https://doi.org/10.1016/j.idcr.2020.e00771>. Available from.
- Wang, D., Hu, B., Hu, C., Zhu, F., Liu, X., Zhang, J., et al., 2020. Clinical characteristics of 138 hospitalized patients with 2019 novel coronavirus-infected pneumonia in wuhan, China. *JAMA, J. Am. Med. Assoc.* 323 (11), 1061–1069.
- Wei, H., Yin, H., Huang, M., Guo, Z., 2020. The 2019 novel coronavirus pneumonia with onset of oculomotor nerve palsy: a case study. *J. Neurol* [Internet], 0123456789. <https://doi.org/10.1007/s00415-020-09773-9>, 3–6. Available from.
- WHO, 2020. WHO Coronavirus Disease 2019 - Situation Report.
- WHO. World Health Organization, 2016. Middle East respiratory syndrome coronavirus (MERS-CoV). Available from: <http://www.who.int/emergencies/mers-cov/en/> [Internet].
- Wu, A., Peng, Y., Huang, B., Ding, X., Wang, X., Niu, P., et al., 2020. Genome composition and divergence of the novel coronavirus (2019-nCoV) originating in China [Internet] *Cell Host Microbe* 27 (3), 325–328. <https://doi.org/10.1016/j.chom.2020.02.001>. Available from.
- Xu, J., Zhong, S., Liu, J., Li, L., Li, Y., Wu, X., et al., 2005. Detection of severe acute respiratory syndrome coronavirus in the brain: potential role of the chemokine mig in pathogenesis. *Clin. Infect. Dis.* 41 (8), 1089–1096.
- Xu, H., Zhong, L., Deng, J., Peng, J., Dan, H., Zeng, X., et al., 2020. High expression of ACE2 receptor of 2019-nCoV on the epithelial cells of oral mucosa [Internet] *Int. J. Oral Sci.* 12 (1), 1–5. <https://doi.org/10.1038/s41368-020-0074-x>. Available from.
- Yang, Y.H., Huang, Y.H., Chuang, Y.H., Peng, C.M., Wang, L.C., Lin, Y.T., et al., 2005. Autoantibodies against human epithelial cells and endothelial cells after severe acute respiratory syndrome (SARS)-associated coronavirus infection. *J. Med. Virol.* 77 (1), 1–7.
- Zanin, L., Saraceno, G., Panciani, P.P., Renisi, G., Signorini, L., Migliorati, K., et al., 2020. SARS-CoV-2 can induce brain and spine demyelinating lesions. *Acta Neurochir (Wien)* 1–4. In Press.
- Zhang, H.F., Zhao, M.G., Liang, G.B., Yu, C.Y., He, W., Li, Z.Q., et al., 2016. Dysregulation of CD4+ T cell subsets in intracranial aneurysm. *DNA Cell Biol.* 35 (2), 96–103.
- Zhao, K., Huang, J., Dai, D., Feng, Y., Liu, L., Nie, S., 2020. Acute Myelitis after SARS-CoV-2 Infection : a Case Report.
- Zhao, H., Shen, D., Zhou, H., Liu, J., Chen, S., 2020. Guillain-Barré syndrome associated with SARS-CoV-2 infection: causality or coincidence? [Internet] *Lancet Glob Heal* (20), 4422. [https://doi.org/10.1016/S1474-4422\(20\)30109-5](https://doi.org/10.1016/S1474-4422(20)30109-5), 2–3. Available from.
- Zhou, F., Yu, T., Du, R., Fan, G., Liu, Y., Liu, Z., et al., 2020. Clinical course and risk factors for mortality of adult inpatients with COVID-19 in Wuhan, China: a retrospective cohort study [Internet] *Lancet* 395 (10229), 1054–1062. [https://doi.org/10.1016/S0140-6736\(20\)30566-3](https://doi.org/10.1016/S0140-6736(20)30566-3). Available from.
- Zhu, N., Zhang, D., Wang, W., Li, X., Yang, B., Song, J., et al., 2020. A novel coronavirus from patients with pneumonia in China, 2019. *N. Engl. J. Med.* 382 (8), 727–733.
- Zochodne, D.W., 2004. SARS, SIRS, and neurological disease. *Arch. Neurol.* 61 (11), 1647–1648.
- Zou, L., Ruan, F., Huang, M., Liang, L., Huang, H., Hong, Z., et al., 2020. SARS-CoV-2 viral load in upper respiratory specimens of infected patients [Internet] *N. Engl. J. Med.* 1 (382;12), 19–21. Available from: <http://www.ncbi.nlm.nih.gov/pubmed/32101656>.