



Guidelines

European interdisciplinary guideline on invasive squamous cell carcinoma of the skin: Part 1. epidemiology, diagnostics and prevention



Alexander J. Stratigos^{a,*}, Claus Garbe^b, Clio Dessinioti^a, Celeste Lebbe^c, Veronique Bataille^d, Lars Bastholt^e, Brigitte Dreno^f, Maria Concetta Fargnoli^g, Ana Maria Forsea^h, Cecille Frenard^f, Catherine A. Harwoodⁱ, Axel Hauschild^j, Christoph Hoeller^k, Lidija Kandolf-Sekulovic^l, R. Kaufmann^m, Nicole WJ. Kelleners-Smeetsⁿ, Josep Malvehy^p, Veronique del Marmol^q, Mark R. Middleton^r, David Moreno-Ramirez^s, Giovanni Pellecani^t, Ketty Peris^{u,v}, Philippe Saiag^w, Marieke H.J. van den Beuken-van Everdingen^o, Ricardo Vieira^x, Iris Zalaudek^y, Alexander M.M. Eggermont^z, Jean-Jacques Grob^{aa} On behalf of the European Dermatology Forum (EDF), the European Association of Dermato-Oncology (EADO) and the European Organization for Research and Treatment of Cancer (EORTC)

^a 1st Department of Dermatology-Venereology, National and Kapodistrian University of Athens, Andreas Sygros Hospital, Athens, Greece

^b Centre for Dermatooncology, Department of Dermatology, Eberhard Karls University, Tuebingen, Germany

^c Université de Paris, INSERM U976, AP-HP, Dermatology Department, Saint Louis Hospital, Paris, France

^d Mount Vernon Cancer Centre, East and North NHS Trust, Northwood, UK

^e Department of Oncology, Odense University Hospital, Odense, Denmark

^f Dermatology Department, CHU Nantes, Université Nantes, CIC 1413, CRCINA Inserm U1232, Nantes, France

^g Dermatology – Department of Biotechnological and Applied Clinical Sciences, University of L'Aquila, L'Aquila, Italy

^h Carol Davila University of Medicine and Pharmacy Bucharest, Department of Oncologic Dermatology, Elias University Hospital Bucharest, Romania

ⁱ Centre for Cell Biology and Cutaneous Research, Blizard Institute, Barts and the London School of Medicine and Dentistry, Queen Mary University of London, UK

^j Department of Dermatology, University Hospital (UKSH), Kiel, Germany

^k Department of Dermatology, Medical University of Vienna, Austria

^l Department of Dermatology, Medical Faculty, Military Medical Academy, Belgrade, Serbia

^m Department of Dermatology, Venereology and Allergology, Frankfurt University Hospital, Frankfurt, Germany

* Corresponding author: 1st Department of Dermatology-Venereology, National and Kapodistrian University of Athens, Andreas Sygros Hospital, Athens, Greece.

E-mail address: alstrat2@gmail.com (A.J. Stratigos).

ⁿ Department of Dermatology, Maastricht University Medical Centre+, GROW Research Institute for Oncology and Developmental Biology, Maastricht University, Maastricht, the Netherlands

^o Centre of Expertise for Palliative Care, Maastricht University Medical Centre+, GROW Research Institute for Oncology and Developmental Biology, Maastricht University, Maastricht, the Netherlands

^p Dermatology Department of Hospital Clinic of Barcelona, University of Barcelona, IDIBAPS, CIBER de Enfermedades Raras, Instituto Carlos III, Spain

^q Department of Dermatology, University Hospital Erasme, Université Libre de Bruxelles, Belgium

^r Department of Oncology, University of Oxford, Oxford, United Kingdom

^s Department of Medical-&-Surgical Dermatology Service, Hospital Universitario Virgen Macarena, Sevilla, Spain

^t Dermatology Unit, University of Modena and Reggio Emilia, Modena, Italy

^u Institute of Dermatology, Università Cattolica, Rome, Italy

^v Fondazione Policlinico Universitario A. Gemelli-IRCCS, Rome, Italy

^w Department of General and Oncologic Dermatology, Ambroise-Paré Hospital, APHP, & EA 4340 “Biomarkers in Cancerology and Hemato-oncology”, UVSQ, Université Paris-Saclay, Boulogne-Billancourt, France

^x Coimbra Hospital and University Centre, Coimbra, Portugal

^y Department of Dermatology, University of Trieste, Italy

^z Princess Máxima Center, 3584, CS Utrecht, the Netherlands

^{aa} Aix Marseille University, APHM Hospital, Marseille France

Received 15 January 2020; accepted 15 January 2020

Available online 26 February 2020

KEYWORDS

Invasive cutaneous squamous cell carcinoma;
Low-risk;
High-risk common primary cSCC;
Locally advanced CscC;
Metastatic cSCC;
Diagnosis;
Prognosis;
Staging;
Imaging;
Prevention

Abstract Invasive cutaneous squamous cell carcinoma (cSCC) is one of the most common cancers in the white populations, accounting for 20% of all cutaneous malignancies. Factors implicated in cSCC etiopathogenesis include ultraviolet radiation exposure and chronic photoaging, age, male sex, immunosuppression, smoking and genetic factors. A collaboration of multidisciplinary experts from the European Dermatology Forum (EDF), the European Association of Dermato-Oncology (EADO) and the European Organisation of Research and Treatment of Cancer (EORTC) was formed to update recommendations on cSCC classification, diagnosis, risk stratification, staging and prevention, based on current literature, staging systems and expert consensus. Common cSCCs are typically indolent tumors, and most have a good prognosis with 5-year cure rates of greater than 90%, and a low rate of metastases (<4%). Further risk stratification into low-risk or high-risk common primary cSCC is recommended based on proposed high-risk factors. Advanced cSCC is classified as locally advanced (lacSCC), and metastatic (mcSCC) including locoregional metastatic or distant metastatic cSCC. Current systems used for staging include the American Joint Committee on Cancer (AJCC) 8th edition, the Union for International Cancer Control (UICC) 8th edition, and Brigham and Women’s Hospital (BWH) system. Physical examination for all cSCCs should include total body skin examination and clinical palpation of lymph nodes, especially of the draining basins. Radiologic imaging such as ultrasound of the regional lymph nodes, magnetic resonance imaging (MRI), computed tomography (CT), positron emission tomography –computed tomography (PET-CT) scans are recommended for staging of high-risk cSCC. Sentinel lymph node biopsy is currently not recommended. Nicotinamide, oral retinoids, and topical 5-FU have been used for the chemoprevention of subsequent cSCCs in high-risk patients but are not routinely recommended. Education about sun protection measures including reducing sun exposure, use of protective clothing, regular use of sunscreens and avoidance of artificial tanning, is recommended.

© 2020 Elsevier Ltd. All rights reserved.

1. Information about the guidelines

1.1. Societies in charge

These Guidelines were developed on behalf of the European Dermatology Forum (EDF), as decided at the

EDF meeting in January 2017. The European Association of Dermato-Oncology (EADO) coordinated the authors’ contributions within its Guideline Program in Oncology (GPO). The editors and coordinators responsible for the formulation of the guideline are: Alexander J. Stratigos, Claus Garbe and Jean-Jacques

Grob. In order to guarantee the interdisciplinary character of these guidelines, they were developed in cooperation with the European Organisation for Research and Treatment of Cancer (EORTC). Twenty-eight experts from 13 countries, all of whom were delegates of national and/or international medical societies, collaborated in the development of these guidelines.

1.2. Financing of these guidelines

The guidelines were supported by grants from the EADO for the guideline meetings. The authors did this work on a voluntary basis and did not receive any honorarium or reimbursements. Guidelines development group members stated their conflicts of interest in the relevant section.

1.3. Disclaimer

The field of medicine is subject to a continuous development process. This entails that all statements, especially with regard to diagnostic and therapeutic procedures, can only reflect scientific knowledge current at the time of printing of these guidelines. Utmost care was applied with respect to stated therapeutic recommendations and the selection as well as dosage of drugs. Nevertheless, users are prompted to use package inserts and expert information by the manufacturers as backup and, in case of doubt, consult a specialist. Pursuant to public interest, questionable discrepancies shall be communicated to the GPO editors. The user remains responsible for all diagnostic and therapeutic applications, medications, and doses. Registered trademarks (protected product names) are not specified in these guidelines. From the absence of respective indications, it may thus not be inferred that product names are unprotected.

This work is protected by copyrights in all its parts. Any utilisation outside the provision of the copyright act without the written permission by the GPO of the EADO is prohibited and punishable by law. No part of this work may be reproduced in any way without written permission by the GPO. This applies, in particular, to duplications, translations, microfilming, and the storage, application, and utilisation in electronic systems, intranets, and internet.

1.4. Scope

These guidelines were written in order to assist clinicians in treating patients with invasive cutaneous squamous cell carcinoma (cSCC). This update was initiated mainly due to advances in systemic treatments and a new AJCC staging system for patients with cSCC, which justify a newer approach to definitions, risk classification and multidisciplinary therapeutic strategies. The use of these guidelines in clinical routine should improve patient care.

1.5. Target population

The present guidelines are published in two parts that both form integral parts of the guidelines: Part 1 contains recommendations with regard to the definitions of cSCC, epidemiology, etiopathogenesis, diagnosis, risk classification, staging and prevention, and Part 2 contains recommendations on treatment, supportive care, patient education and follow-up for patients with cSCC, addressing in detail all different subgroups of cSCC, from the “low-risk primary”, “high-risk primary”, to “locally advanced” and “metastatic” tumors.

1.6. Objectives and formulation of questions

The guidelines are produced primarily for those clinicians who are caring for patients with invasive cSCC. We focus on invasive cSCC (hereafter cSCC), excluding the early intra-epidermal SCC-like actinic keratoses (AK), Bowen’s disease, and mucosal SCCs, such as those located in the genital area, or those in the labial-buccal-nasal area, which are often mixed with cSCC under the label of ‘head and neck’ tumors. Particular emphasis is given to the definitions of cSCC, the diagnosis, risk classification, updated staging systems and treatment modalities. Patient education and prevention issues are also addressed. Formulation of clear sections has been made to support clinicians in their practice.

1.7. Audience and period of validity

This set of guidelines will assist healthcare providers in managing their patients according to the current standards of care and evidence-based medicine. It is not intended to replace accepted national guidelines. The guidelines published here reflect the best published data available at the time the report was prepared. Caution should be exercised in interpreting the data; the results of future studies may modify the conclusions or recommendations in this report. In addition, it may be necessary to deviate from these guidelines for individual patients or under special circumstances. Just as adherence to the guidelines may not constitute defence against a claim of negligence (malpractice), deviation from them should not necessarily be deemed negligent. These guidelines will require updating approximately every 2 years (expiration date: December 2021) but advances in medical sciences may demand an earlier update.

1.8. Principles of methodology

The European Interdisciplinary Guidelines on invasive squamous cell carcinoma of the skin are written as a uniform text and then published in two separate but integral parts: Part 1 on definitions, epidemiology, etiopathogenesis, diagnosis, risk classification, staging and prevention and Part 2 on treatments, supportive

care, patient education and follow-up (Stratigos et al., 2020).

The guidelines published here are an update of the existing European consensus-based (EDF/EADO/EORTC) interdisciplinary guidelines for the management of invasive cSCC (former version 2015) [1] and based on other up-to-date guidelines, including the German S3k guidelines (2019) in press, the National Comprehensive Cancer Network (NCCN) Clinical Practice Guidelines in Oncology for squamous cell skin cancer (version 2.2019) [2], the American Academy of Dermatology (AAD) guidelines (2018) (based on the NCCN risk stratification) [3] and the United Kingdom National Multidisciplinary Guidelines for non-melanoma skin cancer [4].

De novo literature search was conducted by the authors by Medline search in English language publications with last search date on July 20, 2019. Search terms included: ‘cutaneous squamous cell carcinoma’, ‘squamous cell carcinoma’, and ‘advanced, locally advanced, low-risk, high-risk common primary cSCC, locally advanced cSCC, metastatic cSCC’. These terms were combined with ‘diagnosis, prognosis, staging, imaging, prevention, chemoprevention, guidelines, treatment, surgical excision, radiotherapy, adjuvant, systemic, anti-PD-1 antibody, cemiplimab, pembrolizumab, chemotherapy, cetuximab, EGFR-inhibitors, clinical trials, follow up, patient education’. The references cited in selected papers were also searched for further relevant publications. The methodology of these updated guidelines was based on the standards of the Appraisal of Guidelines for Research and Evaluation (AGREE II) instrument [5].

Recommendations are based on the level of best quality available evidence and good clinical practice (GCP).

The levels of evidence were graded according to the Oxford classification (Table 1) [6]. The grades of recommendation were classified as follows:

- A: Strong recommendation. Syntax: ‘shall’.
- B: Recommendation. Syntax: ‘should’.
- C: Weak recommendation. Syntax: ‘may/can’.
- X: Should not be recommended.
- 0: Recommendation pending. Currently not available or not sufficient evidence to make a recommendation in favour or against.

Expert consensus was provided wherever adequate evidence is not available.

1.9. Consensus building process

The consensus building process was conducted as follows: In a first-round medical experts who participated in their national guideline development processes were involved in producing an initial draft. In a second round, the European Organisation for Research and Treatment of Cancer

(EORTC) selected experts from different specialties to contribute to these guidelines. A consensus meeting was held in Athens, Greece, on September 6th and 7th, 2019 with final outcomes: (1) the approval of the text and (2) a consensus rate of agreement of at least 80%, for recommendations provided in structured boxes and the figure. Voting of the recommendations included the selection of ‘Agree’, ‘Disagree’ or ‘Abstention’ vote, and the possibility of providing comments in case of disagree/abstention. Consensus voting on recommendations and finalisation of the draft was conducted among coauthors through emailing between Sept 20th and October 30th, 2019.

There were two recommendations that had a lower-than-80% consensus rate: the recommendation for ‘Imaging for staging’ and the figure for staging. Comments were received from coauthors, the recommendations were revised, and a second round of voting was conducted for these two recommendations.

2. Definitions of cSCC

Cutaneous SCC is a common skin cancer characterised by the malignant proliferation of epidermal keratinocytes and it is classified as a keratinocyte carcinoma together with basal cell carcinoma. [7]. It is distinguished in *in situ* (Bowen’s disease) and invasive form. Cutaneous SCCs originate from a proliferation of keratinocytes, and invasive cSCC is probably often the ultimate step of a long lasting intraepidermal dysplasia. [8,9]. These guidelines focus on invasive cSCC (cSCC).

Depending on the extension of the disease, cSCC is distinguished as common primary, by far the most frequent, and advanced cSCC. Common primary cSCCs are non-metastatic cSCC, usually easy to treat, which can be further classified as low-risk or high-risk, depending on the risk of recurrence. Advanced cSCC is classified as locally advanced (lacSCC), or metastatic (mcSCC) including locoregional metastatic or distant metastatic cSCC, respectively.

LacSCC shall be defined as non-metastatic cSCC, not amenable to either surgery or radiotherapy with reasonable hope for cure, because of multiple recurrences, large extension, bone erosion or invasion, or deep infiltration beyond subcutaneous tissue into muscle or along nerves, or else tumors in which curative resection would result in unacceptable complications, morbidity or deformity [10–12]. This corresponds to unresectable T3/T4 (tumor invading deep structures) according to the 8th edition AJCC or UICC staging classification [13,14].

McSCC includes locoregional metastatic cSCC with in-transit metastases or metastasis to regional lymph nodes, or distant metastatic cSCC requiring systemic treatments. cSCC with regional nodal metastasis corresponds to stage III or IV according to the 8th edition AJCC or UICC staging classification. Metastatic cSCC

Table 1
Oxford centre for evidence-based medicine 2011 level of evidence.

Question	Step 1 (Level 1 ^a)	Step 2 (Level 2 ^a)	Step 3 (Level 3 ^a)	Step 4 (Level 4 ^a)	Step 5 (Level 5)
How common is the problem?	Local and current random sample surveys (or censuses)	Systematic review of surveys that allow matching to local circumstances ^b	Local non-random sample ^b	Case-series ^b	n/a
Is this diagnostic or monitoring test accurate? (Diagnosis)	Systematic review of cross-sectional studies with consistently applied reference standard and blinding	Individual cross-sectional studies with consistently applied reference standard and blinding	Non-consecutive studies, or studies without consistently applied reference standards ^b	Case-control studies, or “poor or non-independent reference standard ^b ”	Mechanism-based reasoning
What will happen if we do not add a therapy? (Prognosis)	Systematic review of inception cohort studies	Inception cohort studies	Cohort study or control arm of randomised trial ^a	Case-series or case-control studies, or poor-quality prognostic cohort study ^b	n/a
Does this intervention help? (Treatment Benefits)	Systematic review of randomised trials or n-of-1 trials	Randomized trial or observational study with dramatic effect	Non-randomized controlled cohort/follow-up study ^b	Case-series, case-control studies, or historically controlled studies ^b	Mechanism-based reasoning
What are the COMMON harms? (Treatment Harms)	Systematic review of randomised trials, systematic review of nested case-control studies, n-of-1 trial with the patient you are raising the question about, or observational study with dramatic effect	Individual randomised trial or (exceptionally) observational study with dramatic effect	Non-randomized controlled cohort/follow-up study (post-marketing surveillance) provided there are sufficient numbers to rule out a common harm. (For long-term harms the duration of follow-up must be sufficient.) ^b	Case-series, case-control, or historically controlled studies ^b	Mechanism-based reasoning
What are the RARE harms? (Treatment Harms)	Systematic review of randomised trials or n-of-1 trial	Randomized trial or (exceptionally) observational study with dramatic effect			
Is this (early detection) test worthwhile? (Screening)	Systematic review of randomised trials	Randomized trial	Non-randomized controlled cohort/follow-up study ^b	Case-series, case-control, or historically controlled studies ^b	Mechanism-based reasoning

^a Level may be graded down on the basis of study quality, imprecision, indirectness (study PICO does not match questions PICO), because of inconsistency between studies, or because the absolute effect size is very small; Level may be graded up if there is a large or very large effect size.

^b As always, a systematic review is generally better than an individual study.

with distant metastasis corresponds to stage IV. The presence of in-transit metastases is not included in the 8th edition AJCC/UICC staging systems.

3. Epidemiology

cSCC is the second most common form of skin cancer, accounting for 20% of keratinocyte carcinomas [7,16]. Ratios of BCC to cSCC range from 2 to 4:1 [16,17]. Most primary cSCC (80%–90%) are located on the head and neck [18]. Reliable population-based cSCC incidence data are limited, sometimes flawed by inclusion of actinic keratosis and in situ SCC, but indicate that rates are increasing in most white populations globally [17,19] and are predicted to continue to increase [19–22].

International incidence data are presented in Table 2 [23–30]. In Australians with a white sun sensitive skin, incidence is rising, although this is not apparent in the population overall because of changes in the proportions of low risk individuals with pigmented skin [31]. Rates increase with age, male sex (SIR, 2.1; 95% confidence interval (CI), 2.06–2.14) and low latitude. Multiplicity is strongly correlated with age [23]. In the UK, between 2013 and 2015, 62.7% of cSCC arose in men (median age 80 years). The mean annual percentage increase was 5% between 2013 and 2015 [25,26]. In Norway, age-adjusted incidence rates increased nine-fold in females and six-fold in males from 1963 to 2011, particularly in the age group 70–79 years [27]. Data from the Swedish Cancer Registry showed higher incidence for populations at the same latitude compared to those resident in coastal areas where hours of sunshine are higher than inland areas [32]. Age-adjusted cSCC incidence data from the northern latitude Rochester Epidemiology Project (USA) reported a 263% increase between 1976–1984 and 2000–2010 and a disproportionate increase in women and people under 40 years [30].

Much of the challenge in obtaining accurate incidence data is related to inconsistent cSCC registration practices in many countries: high incidence, multiplicity

Table 2
International incidence data for cSCC.

Country	Time period	Age-standardized incidence (per 100,000 PY)	Reference
Australia		270	[23]
Queensland		467	
Tasmania		175	
UK	2013–2015	77 in men 34.1 in women (for first cSCC, per annum)	[25,26]
Ireland	1994–2011	66.1 in men 30.6 in women	[24]
Norway	2008–2011	20 in men 15 in women	[27]
USA	2012	In northern latitudes: 46.3–134.5 in men 15.7–42.9 in women In southern latitudes: 233.2–497.1 in men 83.3–180.5 in women	[29]
USA the northern latitude Rochester Epidemiology Project	1976–1984 2000–2010	207.5 in men 128.8 in women	[30]
Japan	2007–2016	Increased from 14.7 to 51.6 in people aged 80 years or more	[28]

PY: person-years.

and low mortality contribute to a tendency to poor ascertainment by cancer registries in which frequently only the first diagnosis of cSCC is recorded, if at all [19,25]. A particularly important consequence is that the associated public health burden of cSCC is substantially underestimated [16,17,20,29,33].

3.1. Prognosis

Common primary cSCC are typically indolent tumors, rarely giving rise to metastasis, when they are treated early and correctly. Most cSCC tumors have a very good prognosis, with 5-year cure rates of greater than 90% [34]. The rate of recurrence was reported to be 4.6% in a large single-centre study of more than 900 patients with cSCC followed for approximately 10 years, 3.7% for nodal disease and 2.1% for disease-specific death [35]. The rate of local recurrence was 3% in a prospective study of 615 patients with surgically resected cSCC, with a 4% rate of metastases, after a median follow up of 43 months [36]. In a large cohort study in the UK, the recurrence rate was 2.7%, and the metastasis rate was 1.2% of which 85% were metastases from head and neck cSCCs [37].

The most recent European data on metastatic risk came from the UK National Cancer Registration and Analysis Service (NCRAS): cumulative incidence of locoregional or distant metastasis after a median follow up of 15.2 months was 2.1% (1.1% in women, 2.4% in

Recommendation 1. Definitions and classifications of invasive cSCC

Definitions and classifications of invasive cSCC	Evidence- based statement
Grade of recommendation: A	Common primary cSCC shall be classified as high-risk or low-risk. Advanced cSCC shall be classified as locally advanced, locoregional metastatic or distant metastatic cSCC.
Level of evidence: 1	Meta-analysis [15], phase 1 and phase 2 cohort studies [12] Strength of consensus: 100%

men) in 2013–15. Most mcSCC (85.2%) were diagnosed within 2 years from the primary cSCC. For most patients with mcSCC, the site of metastasis was the head and neck or parotid lymph nodes (73.6%). Risk increased with age, in males, in patients with immunosuppression, in higher deprivation quintiles, and location on the ear and lip [25].

Immunosuppression in patients with cSCC may include human immunodeficiency virus (HIV) infection, solid organ transplant, haematopoietic stem cell transplant, or chronic lymphocytic leukemia (CLL) [38]. Several studies have shown worse outcomes for cSCC in immunosuppressed patients compared to immunocompetent patients [39,40]. In immunosuppressed patients, locoregional recurrence was more common [39], whereas the risk of metastatic cSCC at least doubled [25] and outcomes for advanced disease were significantly worse [41]. Mortality rates of 494 per 100,000 were reported for the U.S. transplant population [42]; higher risk of recurrence, nodal metastasis and death is also reported in CLL [43–45] and survival after nodal disease in immunosuppressed individuals is significantly reduced [41].

Mortality rates of cSCC are not well documented [17]. A study in the Cancer Registry of Norway for the period from 2000 to 2011, reported five-year relative survival rates for localised cSCC of 88% in women and 82% in men, and of 64% in women and 51% in men for advanced cSCC [27]. A prospective study in 2149 cSCC (1434 patients) reported 2.8% disease-specific death after a median follow-up of 36.5 months [46].

4. Etiopathogenesis

Beside ultraviolet radiation (UVR) exposure (sun exposure and use of tanning beds [47]), which is by far the most important causal factor for cSCC, some others have been implicated such as immunosuppression, BRAF inhibitor (BRAFi) single agent therapy, β -HPV subtypes [48,49] and smoking [50,51].

The main carcinogen for cSCC development is UVR exposure. While most cSCCs will arise in the context of AKs and in patients with chronic photoaging, the rate of transformation of clinically evident AKs into cSCC is very low, at least in a few years period of follow-up (less than 1/1000 per year during a 5-year follow up) [52–54]. Available evidence indicates that incidence rates are consistently highest in fair-skinned populations in geographic locations with high ambient UV exposure; are higher among men than women; increase markedly with age – 80% occur in people over 60, probably because of the driving role of cumulative sun exposure, which increases with age; increase with decreasing deprivation; are more common and have worse prognosis with immunosuppression [17,19,24,25,55].

Markedly increased rates of cSCC have been reported in organ transplant patients [56] and in patients with

chronic lymphocytic leukaemia (CLL) [45] or HIV [57]. Risk was increased by 9 to 18-fold in Danish and US haematopoietic stem cell transplant recipients compared with the general population [58,59]. In a US cohort, HIV patients with CD4 count <200 cells/ml had a 2.2 times increased risk compared to HIV-uninfected individuals for subsequent cSCC after a first cSCC [60].

BRAFi monotherapy with vemurafenib, dabrafenib or encorafenib in patients with metastatic melanoma, has been shown to induce cSCC at higher risk compared to combined BRAF/MEK inhibitors [61]. The mechanism of cSCC development is proposed to be hyperproliferation of keratinocytes due to paradoxical activation of the mitogen-activated protein kinase (MAPK) pathway in wild-type BRAF cells, particularly in the presence of oncogenic RAS mutations [62–64].

The development of cSCC during vismodegib (hedgehog pathway inhibitor) treatment in patients with locally advanced or metastatic BCC has also been reported [65,66].

Photosensitising thiazide antihypertensives have been recently associated with the risk of cSCC development [67,68], however causality has not been substantiated. A meta-analysis by Gandini *et al.* reported no association between thiazide diuretics and cSCC [69]. While a positive association was reported in the meta-analysis of Tang *et al.*, there was no association noted between thiazide use and cSCC risk when only studies that had accounted for sun exposure were included [70].

4.1. Molecular pathogenesis

cSCCs are complex genetic tumors with a high mutation rate [71–73]. Most cSCCs carry a UV mutation signature with characteristic C > T or CC > TT dinucleotide mutations, although these may in part be passenger mutations also found in surrounding photoaged skin [74]. Genes altered in UV-induced SCC include TP53, CDKN2A involved in cell cycle control, NOTCH1 and NOTCH2, the epigenetic regulators KMT2C, KMT2D, TET2 and mutations of TGF β receptors leading to their inactivation [72,73,75]. Genetic alterations that may be targeted with treatments are infrequent but include PIK3CA, fibroblast growth factor receptor 3 (FGFR3), BRAF, and epidermal growth factor receptor (EGFR) [76]. Genetic signatures have been linked to azathioprine exposure in SCC arising in immunosuppressed patients [72] and to hyperactivity of endogenous cytidine deaminases (APOBEC mutation signature) in cSCC in recessive epidermolysis bullosa patients and possibly in other cSCC arising on burn scars or on chronic ulcers [77].

Genome-wide association studies have highlighted single nucleotide polymorphisms associated with cSCC risk, including *MC1R*, *ASIP*, *TYR*, *SLC45A2*, *OCA2*, *IRF4*, *BNC2*, the metastasis suppressor gene *CADMI*, *AHR*, a transcription factor that regulates cell proliferation, and *SEC16A* involved in secretion and cellular

proliferation [78–81]. Microenvironment is implicated in cSCC, with a role for human leukocyte antigen (HLA) variants [82] and the programmed cell death protein 1/programmed cell death ligand-1 (PD-1/PD-L1) axis. PD-L1 expression was detected in around 26% of primary cSCC [83–85] and up to 50% of metastatic lesions [84,85]. Hereditary syndromes that increase cSCC risk include xeroderma pigmentosum, epidermolysis bullosa, oculocutaneous albinism and Fanconi anaemia and Lynch syndrome/Muir Torre syndrome [7].

5. Diagnostic approach of primary cSCC

5.1. Clinical diagnosis

cSCC may have different clinical presentations depending on tumor size, differentiation, pigmentation, location and skin type. It most commonly arises in sun exposed sites (head, neck, upper-limb extremities, dorsum of the hands). One of the strongest predictors of development in previously unaffected individuals is the presence of actinic keratoses and these lesions are a marker of risk rather than precursor lesions as the rate of transformation of individual solar keratoses is very low [53,54].

In its early minimally invasive phase, cSCC is usually a small flesh-coloured plaque or papule, sometimes with a scaly/hyperkeratotic surface, not easily distinguishable from a hyperplastic/hyperkeratotic AK or *in situ* SCC. It enlarges over time with crusting and ulceration. There is usually some induration upon palpation. cSCC can be pigmented, presenting a light to dark brown colour. Well-differentiated cSCCs are usually easy to diagnose hyperkeratotic and verrucous tumors, sometimes more or less crateriform. Poorly differentiated cSCCs appear as red fleshy non-keratotic tumors with frequent ulceration hardly distinguishable from other tumors like amelanotic melanoma, cutaneous metastases or Merkel cell carcinoma. cSCC may be symptomatic, and pain may be generated when pressure is applied to the lesion.

Keratoacanthoma (well-differentiated cSCC, keratoacanthoma-like SCC) is a cSCC with a distinct clinical behaviour including fast growth (a few days or weeks) from normal skin, spontaneous regression and a few distinctive histological criteria [86,87]. Keratoacanthoma is a solitary symmetrical dome-shaped nodule capped with keratin, usually arising on sun-exposed skin areas. Keratoacanthoma can grow to a very large size [86], which is not *per se* a high-risk prognostic factor provided that clinical and histological features are highly suggestive of keratoacanthoma, especially considering the good prognostic outcomes reported in a meta-analysis of keratoacanthoma cases [87].

LacSCC may result either from multiple relapses after incorrect initial management of common primary SCC or directly from highly biologically aggressive

SCC. This results in larger tumors with induration including the surrounding skin and possible invasion of regional anatomic sites such as the orbitae or sinuses with pain and associated symptoms. Actual tumor extent, infiltration and depth of invasion are not really predictable by simple clinical examination. In mcSCC, the tumor may present with in-transit, nodal or distant metastasis. Clinical examination of the draining basins and imaging in addition to clinical diagnosis has to be considered for staging in high-risk cSCC when metastases need to be ruled out.

The clinical differential diagnosis of typical cases is usually easy. Early cases may be differentiated from inflamed seborrheic keratosis, high-grade AK, or keratotic basal cell carcinoma. Less differentiated cases may be confused with amelanotic melanoma, or with rarer neoplasms such as atypical fibroxanthoma, Merkel cell carcinoma or adnexal tumors among others.

Adequate documentation of the cutaneous tumor with measurement of the maximum clinical diameter in the patient's medical file is necessary prior to biopsy and surgery. Recording of symptoms and photography is recommended prior to biopsy. Recording the clinical diameter is important as this is a critical parameter in risk classification and staging of cSCC and not the size recorded in the histologic report, which is usually altered due to sample-processing techniques.

5.2. Dermoscopy and other non-invasive techniques

Dermoscopy, although less frequently performed with non-pigmented than for pigmented lesions, may help in the differential diagnosis of equivocal cases, especially in particular situations, such as in minimally invasive cSCC or in pigmented forms, with the identification of the presence of glomerular-like vessels, clustered vessels, hairpin vessels, scale and alignment of dots and vessels. In keratinizing cSCC, dermoscopy may show structures associated with abnormal keratinization of the hair follicle and adnexal structures with white circles that are more frequent in lesions on the face, also correlating with well-differentiated tumors. [88]. In poorly differentiated cSCC, the presence of red colour, irregular/atypical vessels and the lack of white colour and scale/keratin are diagnostic dermoscopic criteria [89,90].

Other non-invasive techniques such as in-vivo Reflectance Confocal Microscopy (RCM) and Optical Coherence Tomography (OCT) have been used in limited case series but there is insufficient evidence for a routine diagnostic use at this point in time. Although RCM generates characteristics which have good histopathologic correlations (i.e. parakeratosis, atypical keratinocytes, and vascular alterations), the limited laser penetration frequently hampers the full-thickness examination of the tumor. Thus, there is insufficient evidence for a routine diagnostic use at this point in time. A possible role for RCM in clinical practice would be to

differentiate cSCCs from BCCs [91–93]. OCT, in different modalities, provides vertical section of the tissue up to 1–2 mm in depth, and may thus help to separate in situ versus early invasive cSCC [94–96].

5.3. Histopathological diagnosis

The gold standard for the diagnosis of cSCC is histology. A biopsy or excision and histological confirmation should be performed in all clinically suspected cSCCs. A lower threshold for biopsy of suspicious lesions has been proposed for solid organ transplant recipients [97]. Depending on the size of the tumor and treatment approach, an incisional biopsy, i.e. incision or punch biopsy or an excisional biopsy of the entire lesion can be performed initially. Preoperatively, the longest clinical diameter of the lesion (including the peripheral rim of erythema) should be recorded and noted on the surgery report as it is part of further prognostic staging [98].

cSCCs consist of atypical epithelial tumor cell formations that extend beyond the epidermis into the underlying dermis. Like the cells of the stratum spinosum of the epidermis, the cells tend to cornify and horny pearls are formed [16 99]. cSCC may be classified according to the WHO classification of skin tumors (4th edition, 2018) [86] as presented in Table 3. Not yet included in the WHO classification is desmoplastic SCC with a high proportion of stroma and narrow cell strands, which grows markedly infiltrative, perineurally or perivascularly [100]. This type must be separated from the common primary SCC group and it is considered a high-risk histological subtype in the NCCN guidelines [2].

Clinical information to be noted on the biopsy as well as the excision requisition should include patient demographics, the location and the clinical diameter of the lesion as the latter is necessary for staging. The final histopathological report (after excision) should include

Table 3
WHO classification of skin tumors: SCC [86].

	ICD-O code
Squamous cell carcinoma not otherwise specified	8070/3
Keratoacanthoma (synonym: well-differentiated SCC)	8071/3
Acantholytic SCC	8075/3
Spindle cell SCC	8074/3
Verrucous SCC	8051/3
Clear cell SCC	8084/3
Other (uncommon) variants	
SCC with sarcomatoid differentiation	8074/3
Lymphoepithelioma-like carcinoma	8082/3
Pseudovascular SCC	8074/3
SCC with osteoclast-like giant cells	8035/3
SCC in situ (Bowen disease)	8070/2

histological risk factors that are relevant for the staging and prognosis of cSCC including the thickness, depth of invasion, the presence or absence of perineural invasion (PNI), the grade of differentiation and margins status and desmoplastic type. Additional useful histologic features may be recorded including the histological subtype, lymphovascular invasion and calibre of affected nerves with PNI if ≥ 0.1 mm (Table 4). As in melanoma, the maximum vertical tumor thickness is measured in mm, from the granular layer of adjacent normal epidermis to the base of the tumor. The depth of invasion reports the invasion or not into the subcutaneous fat (Clark level V), or even below for more aggressive tumors. For PNI, there is need for standardization in reporting [101]. The histopathological subtypes that have been associated with higher risk for

Table 4
Basic features included in the histopathological report of a cSCC diagnosis (modified from Refs. [1,186]).

Histopathologic Report of cSCC	
Histologic subtype:	<ul style="list-style-type: none"> • Common • Keratoacanthoma • Acantholytic • Spindle cell SCC • Verrucous • Adenosquamous • Clear cell SCC • Desmoplastic • Other:
Degree of differentiation	<ul style="list-style-type: none"> • Well differentiated • Moderately differentiated • Poorly differentiated
Tumor histological thickness ^amm
Invasion beyond subcutaneous fat	<input type="checkbox"/> No <input type="checkbox"/> Yes
Perineural invasion	<input type="checkbox"/> No <input type="checkbox"/> Yes
Lymphatic/vascular invasion	<input type="checkbox"/> No <input type="checkbox"/> Yes
Complete excision:	<input type="checkbox"/> No <input type="checkbox"/> Yes
Minimum lateral margin:mm
Minimum deep margin:mm

^a Tumor thickness measured from the granular layer of adjacent normal epidermis to the base of the tumor (per 8th TNM classification for carcinomas of the skin).

Recommendation 2. Clinical and non-invasive diagnosis of the primary cSCC

Clinical and non-invasive diagnosis of the primary cSCC GCP

Consensus-based statement

Clinical diagnosis of the primary cSCC includes description of the lesion, recording of symptoms and measurement of the diameter. Photographic documentation is strongly recommended. Dermoscopy, and confocal microscopy or OCT if available, can help in the differential diagnosis of cSCC pre-operatively. Strength of consensus: 100%

local recurrence or metastases include desmoplastic, metaplastic (spindle cell), acantholytic (adenoid), or adenosquamous (showing mucin production) subtypes [2], and their presence is a NCCN high-risk criterion. The degree of differentiation may classify cSCC into well-differentiated subtypes with low metastatic potential and in poorly differentiated more aggressive subtypes [16]. The histopathology report should mention peripheral and deep margin status [2].

6. Prognostic factors for high-risk cSCC

All advanced SCCs, whether locally advanced or metastatic have become high-risk tumors by definition, although they may have started as low risk tumors initially undertreated. Indeed, a retrospective study from the German Dermatologic Cooperative Oncology Group (DeCOG) reported that in 190 patients with advanced cSCC, most patients (58%) had a primary tumor with a low T stage (T in situ, T1, T2) [102].

Assessment of the risk is thus particularly relevant for common cSCC to identify the few with a high-risk risk of local recurrence, or metastasis among all the other low-risk tumors. The risk factors may be classified as intrinsic (tumor-related) or extrinsic (patient- and physician-related). Studies reported various prognostic high-risk factors including the maximum clinical diameter (mm) of the tumor [35,36,103], histological thickness [36,46], tumor invasion level [35,103], the presence of desmoplasia [36,46,103], or poor differentiation, PNI, location [35,36], or immunosuppression [36,46]. Guidelines have proposed additional factors including rapid growth, poorly defined borders, site of previous radiotherapy, recurrence and positive margins [2,3]. The variability of high-risk factors proposed is due to the variability of reported evidence. Retrospective studies usually include a small number and/or heterogeneous groups of patients and investigate different outcomes

including local recurrence (LR), nodal metastasis (NM), distant metastasis, disease-specific survival (DSS), and overall survival (OS). Furthermore, the effect of risk factors may vary.

High-risk prognostic factors identified in meta-analyses, staging systems and updated guidelines are summarized in Table 5. A systematic review and meta-analysis in 2016 (36 studies)[15] reported that statistically significant risk factors for recurrence were Breslow tumor thickness >2 mm and >6 mm, invasion beyond subcutaneous fat, (PNI), tumor diameter >20 mm, location on the temple, and poor differentiation. Statistically significant risk factors for nodal metastasis were invasion beyond subcutaneous fat, Breslow >2 mm and >6 mm, diameter >20 mm, poor differentiation, PNI, location on the temple, ear, or lip, and immunosuppression. Factors for disease-specific death were diameter >20 mm, poor differentiation, location on the ear or lip, invasion beyond subcutaneous fat and PNI. Tumor depth was associated with the highest risk of local recurrence and metastasis, while tumor diameter ≥ 20 mm was associated with the highest risk of disease-specific death (DSD). The quality of the reviewed literature was considered to be low-to-moderate [15] (Table 5).

The ascertainment of high-risk prognostic factors defining high-risk cSCC may have an impact on further management, with more aggressive surgical treatment and more regular follow up recommendations. A list of indicative high-risk factors with evidence-based data portending a higher risk of recurrence is proposed in Recommendation 4. These proposed high-risk factors include clinical features (tumor diameter, location, symptomatic PNI), histological features (thickness or deep invasion, poor differentiation, desmoplasia, PNI), radiologic features (radiological PNI, bone erosion) and immunosuppression. In addition, as shown in the BWH staging system, the combination of two or more high-risk factors (among poor differentiation, PNI, clinical diameter and invasion beyond subcutaneous tissue), significantly increases the risk of negative outcomes. In view of current gaps of knowledge on the precise risk of each factor individually, as well as on additional factors influencing this risk, it is recommended to consider the variations of patient- and tumor-related characteristics when assessing the level of overall prognostic risk.

The role of extrinsic risk factors is more difficult to study, but it is clear in the clinical practice, that many compromises in the management of early SCC, whether linked to patient requests to limit extent of surgery or to the physician's wish to simplify treatment, are responsible for a number of complications. Positive margins correspond to residual tumor, which *a priori* has potential for recurrence. When initial removal is incomplete, cSCC is more likely to recur, mostly locally and less frequently in regional lymph nodes [36,37]. A retrospective study in patients with high-risk cSCC

Recommendation 3. Pathology report

Pathology report	Consensus-based statement
GCP	<p>If invasive SCC is suspected, a histopathological diagnosis shall be made.</p> <p>The following histological characteristics shall be included in the pathology report: histological thickness or depth of invasion, grade of differentiation, presence of perineural invasion, desmoplastic type and margins status.</p> <p>It may also include histologic subtype, lymphovascular invasion and calibre of affected nerves with perineural invasion (PNI) if ≥ 0.1 mm</p> <p>Strength of consensus: 100%</p>

Table 5

Prognostic high-risk factors for the primary tumor (T) classification of cSCC in up-to-date staging systems, guidelines and meta-analysis.

	8th ed. AJCC TNM staging (only for head/neck) (2018)	8th ed. UICC TNM staging (2018)	BWH T classification system* (Modified, 2014)	Breuninger T system (2012)	NCCN guidelines (2.2019 version)	Thompson, meta-analysis, 2016	EADO guidelines (2019 update)
Tumor clinical risk factors							
Maximum clinical diameter	+ > 2 cm	+ > 2 cm	+ ≥ 2 cm	+ > 2 cm	≥2 cm area L ≥1 cm area M Any size area H	+ ^{b,c,d} (>2 cm)	+ > 2 cm
Primary tumor site				+ ear		+ ^{b,c,d} (temple ^{b,c} ear ^{c,d} , lip ^{c,d})	+ (temple, ear, lip)
Site of prior RT or chronic inflammatory process					+	NS	
Symptomatic clinical PNI	+	+				NS	+ (pain, numbness, tingling, paralysis or formication)
Neurologic symptoms					+	NS	
Border					+ Poorly defined	NS	
Rapidly growing tumor					+	NS	
Primary versus recurrent					+ Recurrent	NS	
Tumor histological risk factors							
Thickness	+ > 6 mm	+ > 6 mm		+ > 6 mm	+ > 6 mm	+ ^{b,c} (>2 mm and >6 mm)	+ > 6 mm
Invasion beyond subcutaneous fat	+	+	+		+	+ ^{b,c,d}	+
Poor differentiation			+	+ or desmoplastic	+	+ ^{b,c,d}	+
Perineural invasion	+ ((tumor cells in the nerve sheath of a nerve lying deeper than the dermis or measuring ≥0.1 mm or presenting with clinical or radiographic involvement of named nerves)		+ (tumor cells in the nerve sheath of a nerve measuring ≥0.1 mm)		+	+ ^{b,c,d}	+
Lymphatic, or vascular involvement					+	NS	
Acantholytic (adenoid), adenosquamous (mucin production), desmoplastic, or metaplastic (carcinosarcomatous) subtypes					+	NS	+ desmoplasia
Tumor imaging risk factors							
Minor bone erosion	+	+	+ bone invasion			NS	+
Perineural invasion in imaging	+	+				NS	+

NS	+	+	+	+	+	+
Gross cortical/bone marrow, skull base invasion and/or skull base foramen invasion						
Patient risk factors						
Immunosuppression						

BWH: Brigham and Women's Hospital, NS: not studied.
 Area H = 'mask areas' of face (central face, eyelids, eyebrows, periorbital, nose, lips [cutaneous and vermilion], chin, mandible, preauricular and postauricular skin/sulci, temple, ear), genitalia, hands, and feet, Area M = cheeks, forehead, scalp, neck, and pretibial, Area L = trunk and extremities (excluding hands, nail units, pretibia, ankles, feet).
 *Included risk factors found to be strong independent prognostic predictors on multivariate analysis for at least 2 end-points (local recurrence, nodal metastasis, disease-specific death, all-cause death).
 Risk for metastasis. The sign (+) indicates the inclusion of the risk factor.
^b Risk for local recurrence.
^c Risk for nodal metastasis.
^d Risk for disease-specific death.

Recommendation 4. A list of indicative prognostic high-risk factors for recurrence for cSCC proposed by EDF-EADO-EORTC

Tumor- and patient-related/ intrinsic high-risk factors for recurrence	Evidence-based recommendation
Grade of recommendation: B	Prognostic factors for considering a common primary cSCC as high-risk: <ol style="list-style-type: none"> tumor diameter (>20 mm) localisation on temple/ear/lip/area thickness >6 mm or invasion beyond subcutaneous fat poor grade of differentiation desmoplasia microscopic, symptomatic, or radiological PNI bone erosion immunosuppression
Level of evidence: 2	Systematic review and meta-analysis of 36 studies (of which only five prospective). Quality of evidence low to moderate [15]. Retrospective study in patients treated with Mohs micrographic surgery [104]. Retrospective studies [39,100,105,106]. Prospective study for disease-specific survival studying seven risk factors and showing increased risk for increased thickness, desmoplasia, and immunosuppression [46]. Systematic review showing worse prognosis with clinical PNI compared to histological PNI [107]. Strength of consensus: 100%

reported that the accuracy of risk factors for staging systems may be compromised by inadequate excision rather than intrinsic high-risk factors. In patients treated with Mohs surgery, only poor differentiation and invasion beyond the subcutaneous fat were associated with worse prognostic outcomes [104]. Recurrence is not included in this guideline as a high-risk factor for subsequent recurrence, considering that primary recurrence was a result of another underlying high-risk factor.

7. Staging systems for cSCC

Staging systems for cSCC include the UICC 8th edition (Union for International Cancer Control, 2017) [13] and the AJCC 8th edition staging (American Joint Committee on Cancer, 2017) [14], as well as two systems for

T classification, namely the Brigham and Women's Hospital T classification system (BWH)[108] and the staging system used by Breuninger *et al.* (hereinafter referred to as the Breuninger system) [109].

The AJCC and UICC staging systems use the maximum clinical diameter of the primary tumor as the main high-risk feature for the T-category classification. Histological invasion (beyond subcutaneous fat) and the presence of PNI upstages the tumor to T3, and local extension to bone or foramen upstages to T4 [13]. The UICC uses a separate TNM classification for non-head and neck cSCC (Table 6) and head and neck cSCC (Table 7), while the AJCC has only been developed for head and neck cancers (Tables 7 and 8). The 8th edition AJCC staging system (AJCC8) was reported to perform better compared to the 7th edition [110]. However, AJCC8 needs further refinement, as T4 classification is rarely used because very few tumors meet the inclusion criteria and some T2 tumors may be associated with poor outcomes, as noted in cases of poorly differentiated tumors [110]. Another major limitation of the AJCC/UICC staging systems is the heterogeneity of stage III that includes both patients with lymph node metastasis and patients with primary cSCC only. AJCC8 adopts the nodal classification used for the mucosal SCC of the head and neck and there are reports of poor prognostic performance for nodal metastases [111–113].

The BWH classification system for the T stage, was described by Jambusaria-Pahlajani *et al.*, in 2013, with the aim of better prognostic stratification of T2 of AJCC staging [108]. This system was based on a retrospective cohort study in a single academic institution based on a multivariate analysis and provides a quantifiable risk value according to the number of risk factors. Four risk factors were found to be strong independent prognostic predictors on multivariate analysis for at least 2 endpoints of interest: (1) poor differentiation, 2) PNI (of any calibre initially [108], and ≥ 0.1 mm in the modified BWH staging system [114]), 3) diameter ≥ 2 cm (in contrast to AJCC8 that uses a cut-off for diameter of > 2 cm), and 4) invasion beyond subcutaneous tissue. T2 tumors are stratified into a low-risk T2a stage (with one of the above risk factors) with 16% of these patients accounting for all SCC-related events (recurrence, nodal metastasis and/or death) and a high-risk T2b with tumors combining 2–3 risk factors and accounting for 64% of all SCC-related events. T3 stage includes tumors that combine all 4 risk factors, as well as those with bone invasion [108,114]. In the study of Karia *et al.*, BWH T2b/T3 tumors accounted for 70% of nodal metastases and 85% of disease-specific death [114].

Staging systems (AJCC 7th and 8th version, BWH and Breuninger) were compared in a population-based cohort study where the BWH and Breuninger systems performed best in identifying cSCC patients at high risk of metastases [115]. However it was commented that staging systems were still not optimal [116]. Among the 103 patients with metastasis, 37.9% fell in the BWH T2a

Table 6

TNM clinical classification 8th edition for invasive cSCC used by the UICC (2017) (excluding eyelid, head and neck, perianal, vulva and penis) [13]. For the pathological classification, pT and pN categories correspond to the T and N categories.

UICC TNM classification 8th edition	
T- Primary tumor	
TX	Primary tumor cannot be identified
T0	no evidence of primary tumor
Tis	Carcinoma in situ
T1	Tumor ≤ 2 cm in greatest dimension
T2	Tumor > 2 cm and ≤ 4 cm in greatest dimension
T3	Tumor > 4 cm in greatest dimension or minor bone erosion or PNI or deep invasion ^a
T4a	Tumor with gross cortical bone/marrow invasion
T4b	Tumor with axial skeleton invasion including foraminal involvement and vertebral foramen involvement to the epidural space
N- Regional Lymph nodes	
Nx	Regional lymph nodes cannot be assessed
N0	No regional lymph node metastases
N1	Metastasis in a single lymph node ≤ 3 cm in greatest dimension
N2	Metastasis in a single ipsilateral lymph node > 3 cm and ≤ 6 cm in greatest dimension or in multiple ipsilateral nodes all ≤ 6 cm in greatest dimension
N3	Metastasis in a lymph node > 6 cm in greatest dimension
M – Distant Metastasis	
M0	No distant metastasis
M1	Distant metastatic disease ^b

In the case of multiple simultaneous cSCC (excluding eyelid, head/neck, perianal, vulva, penis), the tumor with the highest T category is classified and the number of separate tumors is indicated in parentheses, e.g., T2(5).

^a Deep invasion defined as invasion beyond the subcutaneous fat or > 6 mm (as measured from the granular layer of adjacent normal epidermis to the base of the tumor); PNI for T3 classification is defined as clinical or radiographic involvement of named nerves without foramen or skull base invasion or transgression.

^b Contralateral nodes in non-head-and-neck cSCC are distant metastases.

and 39.8% in BWH T2b category, while with AJCC8 more than 60% fell in the T3 category [115]. AJCC8 was compared with the BWH classification system in the retrospective study of Ruiz *et al.* in 680 primary cSCC of the head and neck. Both systems had similar monotonicity and homogeneity, and the BWH system was reported to be superior in predicting NM and DSD but with no difference for LR and OS [117]. A retrospective study reported that the BWH system trended toward superior risk stratification relative to AJCC8 and UICC8 in 454 patients with cSCC and CLL [118].

These guidelines state that the AJCC8 is basically used for staging of patients with cSCC but is not satisfactory especially for advanced cSCC. The BWH staging system provides a quantifiable measure of risk for recurrence/lymph node metastasis for high-risk patients. It is clear from this detailed analysis of the currently available staging systems that a more practical, and relevant classification system with extensive validation in population-based or cohort studies is needed.

Table 7

pTNM pathological classification 8th edition for invasive cSCC of the head and neck used by the UICC and AJCC (2017) (excluding eyelid for UICC) [13,14].

UICC/AJCC TNM classification 8th edition	
pT – Primary Tumor	
the same as TNM classification for non-head and neck used by UICC in Table 6	
-AJCC uses different definition for PNI ^a	
pN – Regional Lymph Nodes	
NX	Regional lymph nodes cannot be assessed
N0	No regional lymph node metastasis
N1	Metastasis in a single ipsilateral lymph node ≤ 3 cm in greatest dimension without ENE
N2a	Metastasis in single, ipsilateral lymph node ≤ 3 cm with ENE or, >3 cm and ≤ 6 cm in greatest dimension without ENE
N2b	Metastasis in multiple ipsilateral lymph nodes, all ≤ 6 cm in greatest dimension without ENE
N2c	Metastasis in bilateral or contralateral lymph node(s), all ≤ 6 cm in greatest dimension without ENE
N3a	Metastasis in a lymph node >6 cm in greatest dimension without ENE
N3b	Metastasis in a lymph node >3 cm in greatest dimension with ENE or multiple ipsilateral, or any contralateral or bilateral node(s) with ENE
M – Distant Metastasis	
M0	No distant metastasis
M1	Distant metastasis

ENE: extranodal extension.

^a In AJCC staging, perineural invasion for T3 classification is defined as tumour cells within the nerve sheath of a nerve lying deeper than the dermis or measuring 0.1 mm or larger in calibre, or presenting with clinical or radiographic involvement of tumour named nerves without skull base invasion or transgression. In UICC staging, perineural invasion for T3 classification is defined as clinical or radiographic involvement of named nerves without foramen or skull base invasion or transgression.

Table 8

Staging based on AJCC/UICC TNM classification 8th edition for cSCC (2017) (for all locations of cSCC, excluding perianal, vulva and penis^a) [13,14].

Stage 0	Tis	N0	M0
Stage I	T1	N0	M0
Stage II	T2	N0	M0
Stage III	T3	N0	M0
	T1, T2, T3	N1	M0
Stage IVA	T1,T2,T3	N2, N3	M0
	T4	Any N	M0
Stage IVB	Any T	Any N	M1

^a Also excluding skin of the eyelid for UICC staging system.

8. Staging work-up

Recommendations for the staging work-up of cSCC are shown in Fig. 1. Staging for recurrent cSCC is the same as for primary cSCC.

8.1. Physical examination

The diagnosis of cSCC should prompt a complete and careful physical examination including full-body skin

examination and evaluation of the skin surface of the primary site for the presence of in-transit metastasis. Although the global risk of lymph node involvement is relatively low (as much as 5%) in invasive cSCC [35], all patients should undergo a careful clinical examination of the regional lymphatic basins via palpation [36,119]. This approach is sufficient in most low-risk cSCC.

In case of a clinically detected regional node, a fine needle aspiration cytology (FNAC) is recommended [120]. As an alternative to FNAC, ultrasound-guided core biopsy can be done [120]. (Fig. 1).

8.2. Nodal imaging

The need for staging procedures is not well established due to limited data for cSCC from the literature. In patients with common primary cSCC but without palpable lymph nodes imaging for staging is recommended only in patients with high-risk EADO factors.

Specification of the high-risk factors for imaging for detecting non-palpable nodal metastasis cannot be given, as the independent effect of high-risk factors has not been consistently reported. cSCC at higher risk for nodal metastasis according to staging systems include (but are not restricted to) AJCC8 T3/T4 and BWH T2b/T3 [117,121] (Fig. 1). Imaging methods like ultrasonography (US), computed tomography scan (CT) or positron emission tomography computed scan (PET-CT) are more sensitive than clinical examination [119,120,122]. There are limited data on the use of US for nodal metastasis for cSCC. A study of 44 patients with vulvar cSCC and suspected inguinal lymph node metastases, reported that US had a higher sensitivity and negative predictive value than CT, but lower specificity and positive predictive value [123]. A meta-analysis (17 studies) in patients with HNSCC (not cSCC) evaluated radiological imaging modalities including US, US-guided FNAC (USgFNAC), CT, MRI) for the detection of lymph node metastases. USgFNAC showed the highest diagnostic odds ratios (DOR). US performed significantly better than MRI. Mean sensitivity of 87% was highest for US and specificity of 98% was highest for USgFNAC. However, there were only two studies addressing the evaluation of clinically N₀ necks [122].

As lymph node metastases from cSCC may be more superficial and easier to detect on US than those from mucosal SCC, US may be a promising cost-effective minimally invasive staging modality for lymph nodes [119].

8.3. Imaging for lacSCC and distant metastasis

For staging of advanced cSCC, consultation in a multidisciplinary tumor board including a radiologist is mandatory to optimise the use of imaging modalities. In large cSCC or those with possible involvement of

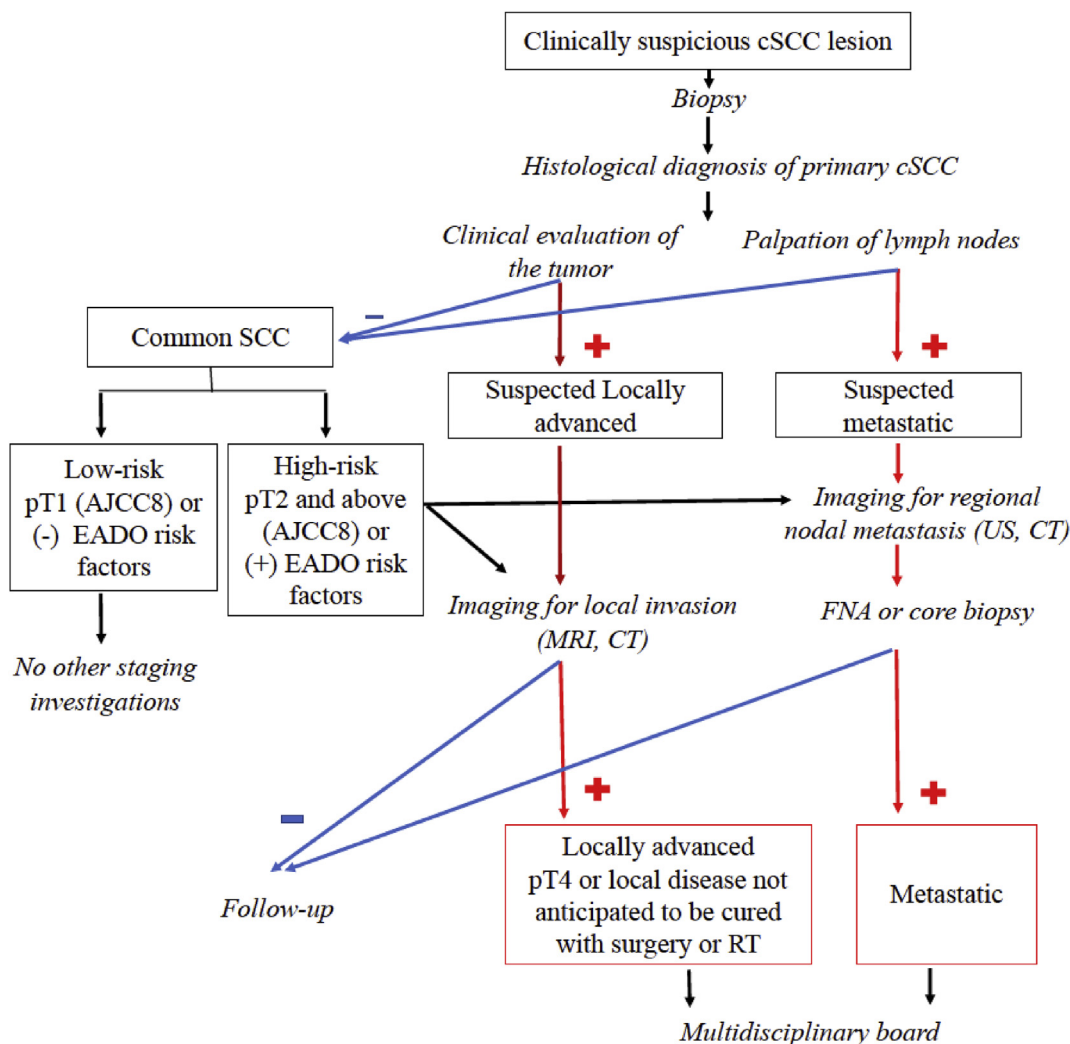


Fig. 1. Algorithm for the diagnostic approach and staging in patients with cSCC. Strength of consensus: 80%. Specification of the high-risk factors for imaging in order to detect non-palpable nodal metastasis cannot be given, as the independent effect of high-risk factors has not been consistently reported. cSCC at higher risk for nodal metastasis according to staging systems include (but are not restricted to) AJCC8 T3/T4 and BWH T2b/T3.

underlying structures (orbital invasion, PNI), additional imaging tests, such as CT or MRI may be required to accurately assess the extent of the tumor and the presence of metastatic spread [107,124–126]. MRI is indicated for subtle intracranial disease, perineural spread [119], and imaging of tumor invasion in surrounding soft tissue [124,126]. CT scan and PET-CT are excellent techniques for the detection of metastatic involvement in distant organs [126] (Fig. 1).

One critical question is whether these radiological investigations help the therapeutic choice with an impact on the course of the disease. A retrospective study of radiologic imaging for high-stage BWH T2b and T3 cSCC in 45 patients reported mainly CT (79%), PET/CT or MRI, while there was no patient in this cohort that underwent imaging with ultrasound. Fifty-eight percent of imaging studies were performed for staging. Imaging changed management in 16 (33%) patients [121].

8.4. Sentinel lymph node biopsy (SLNB)

SLNB for patients with cSCC aims at the detection of occult nodal metastasis with the hope that their early management may improve prognosis. The systematic review of Navarrete-Dechent *et al.*, in 2015 (16 studies), reported an overall positive rate of SLNB of 13.9% (32 of 231 patients) and false-negative rate of 4.6% in cSCC [130]. However, published studies include small number of patients and are heterogeneous [131–135]. The review of the literature by Allen *et al.*, in 2014, reported a sensitivity of 79%, specificity of 100% and a negative predictive value of 96% [136]. The systematic review of Tejera-Vaquero *et al.*, in 2018 (23 studies), reported positive SLNB in 8% of patients with cSCC, and found no studies reporting on predictors of SLN involvement or on the prognostic utility of SLN following adjustment for confounders. The meta-analysis of Schmitt *et al.*, (19 studies, 130 patients with non-anogenital cSCC)

Recommendation 5. Imaging for staging**Imaging for staging of cSCC****Good clinical practice (GCP)****Evidence-based recommendation**

Patients with low-risk cSCC should undergo physical examination only with no need for imaging studies unless needed by clinical examination

Patients with primary common cSCC with high-risk factors should be staged for non-palpable lymph node involvement by US or CT scan. US performed in expert referral centres, may be preferred as a minimally invasive cost-effective imaging modality

For suspected underlying tissue involvement, CT (bone) or MRI (soft tissue) should be done to determine extent of local infiltration. LacSCC should undergo imaging to rule out metastasis. cSCC with nodal involvement should undergo a full skin examination and imaging studies to rule out distant metastatic disease

Level of evidence: 3

There are no precise clinical guidelines for radiologic evaluation for cSCC [124]

Meta-analysis of studies for the detection of lymph nodes metastases in HNSCC (only two studies addressing the evaluation of clinically N₀ necks) [122]

Retrospective studies [121,123,127–129]

Review of studies on nodal staging of high-risk cSCC [119]

Strength of consensus: 80%

Recommendation 6. SLNB**SLNB for cSCC****Grade of recommendation: X****Level of evidence: 3****Evidence-based recommendation**

SLNB is currently not recommended in the management of cSCC outside of the setting of clinical trials

No evidence of prognostic advantage in the detection of occult metastatic disease by SLNBs [130,140]

Meta-analysis [140,141]

Systematic review [138]

Strength of consensus: 100%

investigated the possibility of staging as a predictor of SLNB results. It identified microscopical involvement of the sentinel lymph node in 12.3% of patients, with all cases having tumors larger than 2 cm [137]. The risk of having a positive sentinel lymph node increased with the tumor stage and varied from 0% in AJCC T1 tumors to 60% in AJCC T4 tumors, and reached 7.1% (6/85) in BWH T2a, 29.4% (5/17) in BWH T2b and 50% (3/6) in BWH T3 stages [137]. The systematic review of Ross *et al.*, mentioned that adverse events from SLNB were rarely reported in available studies [138].

In summary, SLNB cannot be currently recommended in invasive cSCC outside of the setting of clinical trials, since evidence is lacking about the real prognostic impact [130] and the characteristics of patients that could eventually benefit from this procedure are not well defined [136,138,139].

9. Primary and secondary prevention

Increased ambient UV exposure, both chronic or intermittent, professional or recreational sun exposure, in childhood and adulthood is associated with an increased risk for SCC. Public health interventions aiming to reduce UV exposure in the general population can be cost-

effective in reducing the incidence and the associated medical costs of skin cancers, including SCC [142–144]. Behavioural interventions have been shown to be effective in increasing sun-protection behaviour, yet there is limited evidence on their effects on reducing sunburns and on improving skin cancer outcomes [145]. Multi-component strategies are considered as most effective for inducing changes in sun exposure behaviour, such as mass media campaigns, environments offering shaded areas, family-oriented behavioural counselling for the early childhood interventions and increasingly digitally delivered interventions [143,145–148]. Messages of sun avoidance between 10 am and 4 pm, wearing long-sleeved clothing, applying sunscreen and avoiding sunbed use, are useful but these interventions are struggling with strong social trends valuing pleasure associated with sunbathing and seaside vacations, and perception of suntan considered as aesthetic as well as a false marker of good health.

Regular use of sunscreen has been reported to be effective in reducing the incidence of SCC in experimental prospective studies [145,149,150]. However a recent meta-analysis did not support the correlation between sunscreen use and skin cancer reduction [151]. It is never too late and a clear message of strict photo-protection should be given to all patients who have already developed cSCC.

Specific situations may require specific preventive and screening measures: In 2010, the International Commission on non-ionizing radiation published a statement on necessary protection of workers against ultraviolet radiation, and in several countries keratinocyte cancer is officially recognized as an occupational disease in outdoor workers [152,153]. Risk-tailored screening procedures were developed for organ transplant recipients in Australia and the UK and similar efforts are under way in the USA [56,154,155].

10. Chemoprevention

Chemoprevention aims to prevent and reduce the risk of the development of new cSCC, especially for patients at

risk of developing numerous and/or aggressive cSCC [163]. Systemic agents tested for the chemoprevention of cSCC include retinoids, nicotinamide and NSAIDs. Oral retinoids studied include acitretin and isotretinoin [163–166], which have shown effective in reducing the incidence of new cSCC at least during the duration of treatment in high-risk patients. They are, however, not routinely recommended, and their use in real life practice as chemopreventive agent is limited as there are significant drawbacks, especially because of their teratogenicity and the dose-related toxicities that are not often tolerated well by patients. [167,168] A systematic review of Chen *et al.*, reported a small number of randomised controlled trials suggesting that acitretin may have a role in the management of solid organ transplant recipients with skin cancers, but the tolerability is a major limiting factor [168]. Nicotinamide is a water-soluble form of vitamin B₃ (niacin). It may enhance repair of photodamaged DNA and prevent the immune-inhibitory effects of UVR [169]. Nicotinamide for 12 months reduced the rate of new cSCC by 30%, but only during active treatment. Nicotinamide was safe and well-tolerated [170–173]. Non-steroidal antiinflammatory drug (NSAIDs) use was associated with reduced risk of SCC in a systematic review and meta-analysis including 9 studies. [174–176] For antioxidants, phytochemicals, vitamin D supplementation and selenium, the current evidence is inconclusive. Vitamin D3 plus calcium had no statistically significant effect in reducing new self-reported NMSC in a RCT in 36,282 postmenopausal women [177].

Topicals for chemoprevention include 5-fluorouracil (5-FU)[163] that was shown to be effective in reducing the risk of cSCC requiring surgery by 75% in one RCT [178]. A 2–4 weeks course appeared to have a protective

effect for one year, with non-significant effect thereafter. Addition of calcipotriol to 5-FU has been shown to increase the benefit [179]. Topical tretinoin has no significant effect in preventing cSCC [180].

10.1. Immunosuppressants in organ transplant recipients

Adjustment or reduction of maintenance immunosuppressive therapy post-transplant may be necessary to reduce the risk of new cSCC and should always be discussed and done in close cooperation with the patient's transplant specialists. Converting therapy from calcineurin inhibitors to newer agents such as mTOR inhibitors and from azathioprine to mycophenolate mofetil are strategies with proven efficiency in this regard [181–185] Converting to mTOR inhibitors after the first new cSCC is recommended. The limitations of mTOR inhibitors are adverse effects and higher risk of death through infectious or cardio-vascular causes. These risks may be mitigated through administration of low-dose sirolimus, which maintained the reduced risk of keratinocyte carcinoma (HR 0.43, 95% CI 0.24–0.78), with a statistically non-significant risk of death (HR 1.07, 95% CI 0.81–1.41) [183].

Funding sources

The development of the current set of guidelines was supported solely by funds of the EADO which were used to mainly support the consensus meeting.

Declaration of competing interest

Dr. Stratigos reports personal fees and/or research support from Novartis, Roche, BMS, Abbvie, Sanofi, Regeneron, Genesis Pharma, outside the submitted work. Dr. Garbe reports personal fees from Amgen, personal fees from MSD, grants and personal fees from Novartis, grants and personal fees from NeraCare, grants and personal fees from BMS, personal fees from Pierre Fabre, personal fees from Philogen, grants and personal fees from Roche, grants and personal fees from Sanofi, outside the submitted work. Dr. Dessinioti has nothing to disclose. Dr. Lebbe reports grants and personal fees from Bristol-Myers Squibb, personal fees from MSD, personal fees from Novartis, personal fees from Amgen, grants and personal fees from Roche, personal fees from Avantis Medical Systems, personal fees from Pierre Fabre, personal fees from Pfizer, personal fees from Incyte, outside the submitted work. Dr. Bataille reports personal fees from Novartis, personal fees from Merck MSD, outside the submitted work. Dr. Bastholt reports personal fees for advisory board activity: BMS, Roche, Novartis, Pierre-Fabre, Astra Zeneca, InCyte, MSD/Merck, Bayer. Dr. Dréno reports grants and personal fees from BMS, personal fees from MSD, grants and personal fees from Roche, grants and personal fees

Recommendation 7. Prevention

Prevention GCP	Evidence-based recommendation
Level of evidence 1	Education about sun protection measures including avoidance of sun bathing, use of protective clothing, regular use of sunscreens and avoidance of artificial tanning, shall be recommended
Level of evidence 1	Behavioural counselling interventions should be recommended
Level of evidence 1	Systematic review of randomised controlled trials, 4 RCT [142,143,145–148,156–158]
Level of evidence 1	Regular use of sunscreens
Level of evidence 2	Systematic search of the literature de-novo. 4 RCT confirmed reduction in SCC rate [149,150]
Level of evidence 2	Public health interventions to reduce UV exposure in general population
	2 RCT and 5 before and after trials [142,143,145,146,159–162]
	Strength of consensus: 100%

from Fabre, grants and personal fees from Sanofi, outside the submitted work. Dr. Fagnoli reports grants and personal fees from Almirall, grants and personal fees from Leo Pharma, personal fees from Janssen, grants and personal fees from Novartis, personal fees from Lilly, grants and personal fees from Sanofi, personal fees from UCB, grants and personal fees from Abbvie, personal fees from Celgene, personal fees from Pierre Fabre, grants and personal fees from Galderma, personal fees from Mylan, personal fees from Medac Pharma, personal fees from Roche, personal fees from Sun Pharma, outside the submitted work. Dr. Forsea reports scientific consultant/speaker fee from Novartis, Leo Pharma, Solartium, Pierre-Fabre, outside the submitted work. Dr. Frenard has nothing to disclose. Dr. Harwood reports institutional research grants and honoraria from Sanofi, Novartis, Merck, Pfizer, Galderma, MEDA, Almirall, Pellepharm, Leo Pharma, CERIES. Dr. Hauschild reports honoraria and/or research grants from: Almirall, BMS, Roche, Novartis, Pierre-Fabre, Sunpharma, MerckSerono, SanofiAventis, Regeneron, MSD/Merck, Philogen, OncoSec outside the submitted work. Dr. Hoeller reports grants and personal fees from Amgen, personal fees from BMS, personal fees from MSD, personal fees from Novartis, personal fees from Pierre Fabre, personal fees from Roche, personal fees from Sanofi, personal fees from Incyte, outside the submitted work. Dr. Kandolf-Sekulovic reports speakers' honoraria from Roche, Novartis, MSD, BMS, Janssen outside the submitted work. Dr. Kaufmann reports institutional research grants (clinical trials) from: AbbVie, Amgen, Biontech, BMS, Celgene, Galderma, Janssen, Leo, Lilly, Merck, MSD, Novartis, Pierre Fabre, Pfizer, Regeneron, Roche, Wyeth. Advisory Board and Honoraria from Merz, Roche, Novartis. Dr. Kelleners-Smeets reports grants from Netherlands Organization for Health Research and Development, other from Janssen-Cilag, other from AbbVie, other from Galderma, outside the submitted work. Dr. Malvey reports research grants from Almirall, ISDIN, Leo Pharma, Galderma, GSK, Cantabria; participation in advisory board meetings for Almirall, Sunpharma, BMS, Roche, Novartis, Pierre-Fabre. Dr. del Marmol reports personal fees from MSD, from BMS, personal fees from Sanofi, grants and personal fees from ABVIE, grants from Jansen, outside the submitted work. Dr. Middleton reports personal fees and/or grants from Amgen, Roche, Astrazeneca, GSK, Novartis, Immunocore, BMS, Eisai and Merck. Institutional funding from Millennium, Vertex, Pfizer, Regeneron, TCBiopharma, BiolineRx, Replimune, outside the submitted work. Dr. Moreno-Ramírez has nothing to disclose. Dr. Pellicani reports grants from university of modena and reggio emilia, during the conduct of the study; grants from novartis, grants and personal fees from almirall, grants from leo pharma, from null, outside the submitted work. Dr. Peris reports honoraria for advisory board and grants from AbbVie, Almirall,

Biogen Celgene, Lilly, Galderma, Leo Pharma, Novartis, Roche, Sanofi, Sun Pharma, Sandoz outside the submitted work. Dr. Saiag reports honoraria for advisory board and grants from Amgen, Bristol-Myers Squibb, MSD, Merck-Serono, Novartis, Pfizer, Roche-Genentech, Pierre Fabre, and Sanofi, outside the submitted work. Dr. van den Beuken-van Everdingen has nothing to disclose. Dr. Vieira has nothing to disclose. Dr. Zalaudek reports honoraria and advisory board and grants from Sanofi, Sun Pharma, Novartis, Galderma, Roche, Celgene, Almirall, Leofarma, Mylan, Difa Cooper, Cieffe Labs, La Roche Posay, Pierre Fabre. Dr. Eggermont reports over the last 5 years personal fees as a consultant advisor for Biocad, BioInvent, Bristol Myers Squibb (BMS), Catalym, Ellipses, Glaxo Smith Kline (GSK), HalioDX, Incyte, IO Biotech, ISA Pharmaceuticals, Merck Sharpe & Dohme (MSD), Novartis, Pfizer, Polynoma, Regeneron, Sanofi, Sellas, SkylineDx. Dr. Grob reports personal fees for advisory board and as speaker from Amgen, Roche, GSK, Novartis, BMS, Pierre fabre, Merck, Sanofi, Merck, Pfizer outside the submitted work.

References

- [1] Stratigos A, Garbe C, Lebbe C, Malvey J, del Marmol V, Pehamberger H, et al. Diagnosis and treatment of invasive squamous cell carcinoma of the skin: European consensus-based interdisciplinary guideline. *Eur J Cancer* 2015;51:1989–2007.
- [2] National Comprehensive Cancer Network. NCCN clinical practice guidelines in oncology. squamous cell skin cancer. version 2.2019-October 23, 2018 ed. Available at NCCN.org.
- [3] Work G, Invited R, Kim JYS, Kozlow JH, Mittal B, Moyer J, et al. Guidelines of care for the management of cutaneous squamous cell carcinoma. *J Am Acad Dermatol* 2018;78:560–78.
- [4] Newlands C, Currie R, Memon A, Whitaker S, Woolford T. Non-melanoma skin cancer: United Kingdom National Multidisciplinary Guidelines. *J Laryngol Otol* 2016;130:S125–32.
- [5] Brouwers MC, Kho ME, Browman GP, Burgers JS, Cluzeau F, Feder G, et al. AGREE II: advancing guideline development, reporting and evaluation in health care. *CMAJ* 2010;182:E839–42.
- [6] Howick J, Chalmers I, Glasziou P, Greenhalgh T, Heneghan C, Liberati A, et al. In: Group OLoEW, editor. the oxford levels of evidence 2: Oxford Center for Evidence-Based Medicine. <https://www.cebm.net/index.aspx?o=5653>. Access Date: 23 April 2019.
- [7] Nagarajan P, Asgari MM, Green AC, Guhan SM, Arron ST, Proby CM, et al. Keratinocyte carcinomas: current concepts and future research priorities. *Clin Canc Res: An Off J Am Assoc Canc Res* 2019;25:2379–91.
- [8] Schmitz L, Gambichler T, Kost C, Gupta G, Stucker M, Stockfleth E, et al. Cutaneous squamous cell carcinomas are associated with basal proliferating actinic keratoses. *Br J Dermatol* 2019;180:916–21.
- [9] Fernandez-Figueras MT, Carrato C, Saenz X, Puig L, Musulen E, Ferrandiz C, et al. Actinic keratosis with atypical basal cells (AK I) is the most common lesion associated with invasive squamous cell carcinoma of the skin. *J Eur Acad Dermatol Venereol* 2015;29:991–7.
- [10] FDA. Libtayo (cemiplimab-rwlc) full prescribing information. Available at: https://www.accessdata.fda.gov/drugsatfda_docs/label/2018/761097s0001bl.pdf. [Accessed 15 July 2019].
- [11] European Medicines Agency. Libtayo. Summary of product characteristics. Available at: https://www.ema.europa.eu/en/documents/product-information/libtayo-epar-product-information_en.pdf. [Accessed 17 July 2019].

- [12] Migden MR, Rischin D, Schmults CD, Guminski A, Hauschild A, Lewis KD, et al. PD-1 blockade with cemiplimab in advanced cutaneous squamous-cell carcinoma. *N Engl J Med* 2018;379:341–51.
- [13] Union for International Cancer Control. TNM Classification of malignant tumours. Eighth edition. Oxford: WILEY Blackwell; 2017.
- [14] Amin MB, Edge S, Greene F, Byrd DR, Brookland RK, Washington MK, Gershenwald JE, Compton CC, Hess KR, Sullivan DC, Jessup JM, Brierley JD, Gaspar LE, Schilsky RL, Balch CM, Winchester DP, Asare EA, Madera M, Gress DM, Meyer LR. In: AJCC cancer staging manual. Eighth Edition. Switzerland: Springer; 2017.
- [15] Thompson AK, Kelley BF, Prokop LJ, Murad MH, Baum CL. Risk factors for cutaneous squamous cell carcinoma recurrence, metastasis, and disease-specific death: a systematic review and meta-analysis. *JAMA Dermatol* 2016;152:419–28.
- [16] Que SKT, Zwald FO, Schmults CD. Cutaneous squamous cell carcinoma: Incidence, risk factors, diagnosis, and staging. *J Am Acad Dermatol* 2018;78:237–47.
- [17] Green AC, Olsen CM. Cutaneous squamous cell carcinoma: an epidemiological review. *Br J Dermatol* 2017;177:373–81.
- [18] Alam M, Ratner D. Cutaneous squamous-cell carcinoma. *N Engl J Med* 2001;344:975–83.
- [19] Lomas A, Leonardi-Bee J, Bath-Hextall F. A systematic review of worldwide incidence of non-melanoma skin cancer. *Br J Dermatol* 2012;166:1069–80.
- [20] Goon PKC, Greenberg DC, Igali L, Levell NJ. Predicted cases of U.K. skin squamous cell carcinoma and basal cell carcinoma in 2020 and 2025: horizon planning for National Health Service dermatology and dermatopathology. *Br J Dermatol* 2017;176:1351–3.
- [21] Glass AG, Hoover RN. The emerging epidemic of melanoma and squamous cell skin cancer. *JAMA* 1989;262:2097–100.
- [22] Gray DT, Suman VJ, Su WP, Clay RP, Harmsen WS, Roenigk RK. Trends in the population-based incidence of squamous cell carcinoma of the skin first diagnosed between 1984 and 1992. *Arch Dermatol* 1997;133:735–40.
- [23] Pandeya N, Olsen CM, Whiteman DC. The incidence and multiplicity rates of keratinocyte cancers in Australia. *Med J Aust* 2017;207:339–43.
- [24] Deady S, Sharp L, Comber H. Increasing skin cancer incidence in young, affluent, urban populations: a challenge for prevention. *Br J Dermatol* 2014;171:324–31.
- [25] Venables ZC, Autier P, Nijsten T, Wong KF, Langan SM, Rous B, et al. Nationwide incidence of metastatic cutaneous squamous cell carcinoma in England. *JAMA Dermatol* 2019;155:298–306.
- [26] Venables ZC, Nijsten T, Wong KF, Autier P, Broggio J, Deas A, et al. Epidemiology of basal and cutaneous squamous cell carcinoma in the U.K. 2013–15: a cohort study. *Br J Dermatol* 2019;181:474–82.
- [27] Robsahm TE, Helsing P, Veierod MB. Cutaneous squamous cell carcinoma in Norway 1963–2011: increasing incidence and stable mortality. *Cancer Med* 2015;4:472–80.
- [28] Umezono Y, Sato Y, Noto M, Yamada K, Noguchi N, Hasunuma N, et al. Incidence rate of cutaneous squamous cell carcinoma is rapidly increasing in Akita Prefecture: Urgent alert for super-aged society. *J Dermatol* 2019;46:259–62.
- [29] Karia PS, Han J, Schmults CD. Cutaneous squamous cell carcinoma: estimated incidence of disease, nodal metastasis, and deaths from disease in the United States, 2012. *J Am Acad Dermatol* 2013;68:957–66.
- [30] Muzic JG, Schmitt AR, Wright AC, Alniemi DT, Zubair AS, Olazagasti Lourido JM, et al. Incidence and trends of basal cell carcinoma and cutaneous squamous cell carcinoma: a population-based study in olmsted county, minnesota, 2000 to 2010. *Mayo Clin Proc* 2017;92:890–8.
- [31] Czarnecki D. Non-melanoma skin cancer mortality rising in susceptible Australians. *J Eur Acad Dermatol Venereol* 2017;31:e286–7.
- [32] Andersson EM, Paoli J, Wastensson G. Incidence of cutaneous squamous cell carcinoma in coastal and inland areas of Western Sweden. *Canc Epidemiol* 2011;35:e69–74.
- [33] Carucci JA. Press for an underestimated nemesis. *JAMA Dermatol* 2013;149:1147–8.
- [34] Brougham ND, Dennett ER, Cameron R, Tan ST. The incidence of metastasis from cutaneous squamous cell carcinoma and the impact of its risk factors. *J Surg Oncol* 2012;106:811–5.
- [35] Schmults CD, Karia PS, Carter JB, Han J, Qureshi AA. Factors predictive of recurrence and death from cutaneous squamous cell carcinoma: a 10-year, single-institution cohort study. *JAMA Dermatol* 2013;149:541–7.
- [36] Brantsch KD, Meisner C, Schonfisch B, Trilling B, Wehner-Caroli J, Rocken M, et al. Analysis of risk factors determining prognosis of cutaneous squamous-cell carcinoma: a prospective study. *Lancet Oncol* 2008;9:713–20.
- [37] Nelson TG, Ashton RE. Low incidence of metastasis and recurrence from cutaneous squamous cell carcinoma found in a UK population: Do we need to adjust our thinking on this rare but potentially fatal event? *J Surg Oncol* 2017;116:783–8.
- [38] Xu MJ, Lazar AA, Garsa AA, Arron ST, Ryan WR, El-Sayed IH, et al. Major prognostic factors for recurrence and survival independent of the American Joint Committee on Cancer eighth edition staging system in patients with cutaneous squamous cell carcinoma treated with multimodality therapy. *Head Neck* 2018;40:1406–14.
- [39] Manyam BV, Garsa AA, Chin RI, Reddy CA, Gastman B, Thorstad W, et al. A multi-institutional comparison of outcomes of immunosuppressed and immunocompetent patients treated with surgery and radiation therapy for cutaneous squamous cell carcinoma of the head and neck. *Cancer* 2017;123:2054–60.
- [40] Rabinovics N, Mizrahi A, Hadar T, Ad-El D, Feinmesser R, Guttman D, et al. Cancer of the head and neck region in solid organ transplant recipients. *Head Neck* 2014;36:181–6.
- [41] Lam JKS, Sundaresan P, GebSKI V, Veness MJ. Immunocompromised patients with metastatic cutaneous nodal squamous cell carcinoma of the head and neck: Poor outcome unrelated to the index lesion. *Head Neck* 2018;40:985–92.
- [42] Garrett GL, Lowenstein SE, Singer JP, He SY, Arron ST. Trends of skin cancer mortality after transplantation in the United States: 1987 to 2013. *J Am Acad Dermatol* 2016;75:106–12.
- [43] Mehrany K, Weenig RH, Lee KK, Pittelkow MR, Otley CC. Increased metastasis and mortality from cutaneous squamous cell carcinoma in patients with chronic lymphocytic leukemia. *J Am Acad Dermatol* 2005;53:1067–71.
- [44] Velez NF, Karia PS, Vartanov AR, Davids MS, Brown JR, Schmults CD. Association of advanced leukemic stage and skin cancer tumor stage with poor skin cancer outcomes in patients with chronic lymphocytic leukemia. *JAMA Dermatol* 2014;150:280–7.
- [45] Brewer JD, Shanafelt TD, Khezri F, Sosa Seda IM, Zubair AS, Baum CL, et al. Increased incidence and recurrence rates of non-melanoma skin cancer in patients with non-Hodgkin lymphoma: a Rochester Epidemiology Project population-based study in Minnesota. *J Am Acad Dermatol* 2015;72:302–9.
- [46] Eigentler TK, Leiter U, Hafner HM, Garbe C, Rocken M, Breuninger H. Survival of patients with cutaneous squamous cell carcinoma: results of a prospective cohort study. *J Invest Dermatol* 2017;137:2309–15.
- [47] Morris KL, Luke MC, Perna FM. Prevalence of skin cancer examination among users of indoor tanning beds. *JAMA Dermatol* 2018;154:840–2.
- [48] Chahoud J, Semaan A, Chen Y, Cao M, Rieber AG, Rady P, et al. Association between beta-Genus human papillomavirus and cutaneous squamous cell carcinoma in immunocompetent individuals-A meta-analysis. *JAMA Dermatol* 2016;152:1354–64.

- [49] Conforti C, Paolini F, Venuti A, Dianzani C, Zalaudek I. The detection rate of human papillomavirus in well-differentiated squamous cell carcinoma and keratoacanthoma: is there new evidence for a viral pathogenesis of keratoacanthoma? *Br J Dermatol* 2019;181:1309–11.
- [50] Pirie K, Beral V, Heath AK, Green J, Reeves GK, Peto R, et al. Heterogeneous relationships of squamous and basal cell carcinomas of the skin with smoking: the UK Million Women Study and meta-analysis of prospective studies. *Br J Canc* 2018;119:114–20.
- [51] Dusingize JC, Olsen CM, Pandeya NP, Subramaniam P, Thompson BS, Neale RE, et al. Cigarette smoking and the risks of basal cell carcinoma and squamous cell carcinoma. *J Invest Dermatol* 2017;137:1700–8.
- [52] Dotto GP, Rustgi AK. Squamous cell cancers: a unified perspective on biology and genetics. *Canc cell* 2016;29:622–37.
- [53] Marks R, Rennie G, Selwood TS. Malignant transformation of solar keratoses to squamous cell carcinoma. *Lancet (London, England)* 1988;1:795–7.
- [54] Werner RN, Sammain A, Erdmann R, Hartmann V, Stockfleth E, Nast A. The natural history of actinic keratosis: a systematic review. *Br J Dermatol* 2013;169:502–18.
- [55] Harwood CA, Arron ST, Proby CM, Asgari MM, Bouwes Bavinck JN, Green AC, et al. Organ transplantation and cutaneous squamous cell carcinoma: progress, pitfalls and priorities in immunosuppression-associated keratinocyte carcinoma. *Br J Dermatol* 2017;177:1150–1.
- [56] Garrett GL, Blanc PD, Boscardin J, Lloyd AA, Ahmed RL, Anthony T, et al. Incidence of and risk factors for skin cancer in organ transplant recipients in the United States. *JAMA Dermatol* 2017;153:296–303.
- [57] Omland SH, Ahlstrom MG, Gerstoft J, Pedersen G, Mohey R, Pedersen C, et al. Risk of skin cancer in patients with HIV: A Danish nationwide cohort study. *J Am Acad Dermatol* 2018;79:689–95.
- [58] Wu PA, Stern RS, Huang V, Liu KX, Chen CA, Tzachanis D, et al. Reduced-intensity conditioning regimens, prior chronic lymphocytic leukemia, and graft-versus-host disease are associated with higher rates of skin cancer after allogeneic hematopoietic stem cell transplantation. *J Invest Dermatol* 2019;139:591–9.
- [59] Omland SH, Gniadecki R, Haedersdal M, Helweg-Larsen J, Omland LH. Skin cancer risk in hematopoietic stem-cell transplant recipients compared with background population and renal transplant recipients: a population-based cohort study. *JAMA Dermatol* 2016;152:177–83.
- [60] Asgari MM, Ray GT, Quesenberry Jr CP, Katz KA, Silverberg MJ. Association of multiple primary skin cancers with human immunodeficiency virus infection, CD4 Count, and viral load. *JAMA Dermatol* 2017;153:892–6.
- [61] Peng L, Wang Y, Hong Y, Ye X, Shi P, Zhang J, et al. Incidence and relative risk of cutaneous squamous cell carcinoma with single-agent BRAF inhibitor and dual BRAF/MEK inhibitors in cancer patients: a meta-analysis. *Oncotarget* 2017;8:83280–91.
- [62] Heidorn SJ, Milagre C, Whittaker S, Nourry A, Niculescu-Duvas I, Dhomen N, et al. Kinase-dead BRAF and oncogenic RAS cooperate to drive tumor progression through CRAF. *Cell* 2010;140:209–21.
- [63] Poulikakos PI, Zhang C, Bollag G, Shokat KM, Rosen N. RAF inhibitors transactivate RAF dimers and ERK signalling in cells with wild-type BRAF. *Nature* 2010;464:427–30.
- [64] Su F, Viros A, Milagre C, Trunzer K, Bollag G, Spleiss O, et al. RAS mutations in cutaneous squamous-cell carcinomas in patients treated with BRAF inhibitors. *N Engl J Med* 2012;366:207–15.
- [65] Mohan SV, Chang J, Li S, Henry AS, Wood DJ, Chang AL. Increased risk of cutaneous squamous cell carcinoma after vismodegib therapy for basal cell carcinoma. *JAMA Dermatol* 2016;152:527–32.
- [66] Jacobsen AA, Aldahan AS, Hughes OB, Shah VV, Strasswimmer J. Hedgehog pathway inhibitor therapy for locally advanced and metastatic basal cell carcinoma: a systematic review and pooled analysis of interventional studies. *JAMA Dermatol* 2016;152:816–24.
- [67] Su KA, Habel LA, Achacoso NS, Friedman GD, Asgari MM. Photosensitizing antihypertensive drug use and risk of cutaneous squamous cell carcinoma. *Br J Dermatol* 2018;179:1088–94.
- [68] Pedersen SA, Gaist D, Schmidt SAJ, Holmich LR, Friis S, Pottegard A. Hydrochlorothiazide use and risk of nonmelanoma skin cancer: A nationwide case-control study from Denmark. *J Am Acad Dermatol* 2018;78:673–681 e9.
- [69] Gandini S, Palli D, Spadola G, Bendinelli B, Cocorocchio E, Stanganelli I, et al. Anti-hypertensive drugs and skin cancer risk: A review of the literature and meta-analysis. *Crit Rev Oncol Hematol* 2018;122:1–9.
- [70] Tang H, Fu S, Zhai S, Song Y, Asgari MM, Han J. Use of antihypertensive drugs and risk of keratinocyte carcinoma: A meta-analysis of observational studies. *Pharmacoevidemiol Drug Saf* 2018;27:279–88.
- [71] South AP, Purdie KJ, Watt SA, Haldenby S, den Breems N, Dimon M, et al. NOTCH1 mutations occur early during cutaneous squamous cell carcinogenesis. *J Invest Dermatol* 2014;134:2630–8.
- [72] Inman GJ, Wang J, Nagano A, Alexandrov LB, Purdie KJ, Taylor RG, et al. The genomic landscape of cutaneous SCC reveals drivers and a novel azathioprine associated mutational signature. *Nat Commun* 2018;9:3667.
- [73] Chitsazzadeh V, Coarfa C, Drummond JA, Nguyen T, Joseph A, Chilukuri S, et al. Cross-species identification of genomic drivers of squamous cell carcinoma development across preneoplastic intermediates. *Nat Commun* 2016;7:12601.
- [74] Alexandrov LB, Nik-Zainal S, Wedge DC, Aparicio SA, Behjati S, Biankin AV, et al. Signatures of mutational processes in human cancer. *Nature* 2013;500:415–21.
- [75] Cammareri P, Rose AM, Vincent DF, Wang J, Nagano A, Libertini S, et al. Inactivation of TGFbeta receptors in stem cells drives cutaneous squamous cell carcinoma. *Nat Commun* 2016;7:12493.
- [76] Al-Rohil RN, Tarasen AJ, Carlson JA, Wang K, Johnson A, Yelensky R, et al. Evaluation of 122 advanced-stage cutaneous squamous cell carcinomas by comprehensive genomic profiling opens the door for new routes to targeted therapies. *Cancer* 2016;122:249–57.
- [77] Cho RJ, Alexandrov LB, den Breems NY, Atanasova VS, Farshchian M, Purdom E, et al. APOBEC mutation drives early-onset squamous cell carcinomas in recessive dystrophic epidermolysis bullosa. *Sci Transl Med* 2018;10.
- [78] Chahal HS, Lin Y, Ransohoff KJ, Hinds DA, Wu W, Dai HJ, et al. Genome-wide association study identifies novel susceptibility loci for cutaneous squamous cell carcinoma. *Nat Commun* 2016;7:12048.
- [79] Wang W, Jorgenson E, Whittemore AS, Asgari MM. Susceptibility loci-associated cutaneous squamous cell carcinoma invasiveness. *J Invest Dermatol* 2018;138:557–61.
- [80] Ioannidis NM, Wang W, Furlotte NA, Hinds DA, andMe Research T, Bustamante CD, et al. Gene expression imputation identifies candidate genes and susceptibility loci associated with cutaneous squamous cell carcinoma. *Nat Commun* 2018;9:4264.
- [81] Sordillo JE, Kraft P, Wu AC, Asgari MM. Quantifying the polygenic contribution to cutaneous squamous cell carcinoma risk. *J Invest Dermatol* 2018;138:1507–10.
- [82] Yesantharao P, Wang W, Ioannidis NM, Demehri S, Whittemore AS, Asgari MM. Cutaneous squamous cell cancer (cSCC) risk and the human leukocyte antigen (HLA) system. *Human Immunol* 2017;78:327–35.
- [83] Varki V, Ioffe OB, Bentzen SM, Heath J, Cellini A, Feliciano J, et al. PD-L1, B7-H3, and PD-1 expression in immunocompetent vs. immunosuppressed patients with cutaneous squamous cell carcinoma. *Canc Immunol Immunother* 2018;67:805–14.

- [84] Schaper K, Kother B, Hesse K, Satzger I, Gutzmer R. The pattern and clinicopathological correlates of programmed death-ligand 1 expression in cutaneous squamous cell carcinoma. *Br J Dermatol* 2017;176:1354–6.
- [85] Garcia-Diez I, Hernandez-Ruiz E, Andrades E, Gimeno J, Ferrandiz-Pulido C, Yebenes M, et al. PD-L1 expression is increased in metastasizing squamous cell carcinomas and their metastases. *Am J Dermatopathol* 2018;40:647–54.
- [86] Murphy GF, Beer TW, Cerio R, Kao GF, Nagore E, Pulitzer MP. Squamous cell carcinoma. In: Elder DM, Scolyer D, R.A., Willemze R, editors. WHO classification of skin tumors. 4th ed. France: International Agency of Research on Cancer (IARC); 2018. p. 35–44.
- [87] Savage JA, Maize JC, Sr. Keratoacanthoma clinical behavior: a systematic review. *Am J Dermatopathol* 2014;36:422–9.
- [88] Rosendahl C, Cameron A, Argenziano G, Zalaudek I, Tschandl P, Kittler H. Dermoscopy of squamous cell carcinoma and keratoacanthoma. *Arch Dermatol* 2012;148:1386–92.
- [89] Lallas A, Pyne J, Kyrgidis A, Andreani S, Argenziano G, Cavaller A, et al. The clinical and dermoscopic features of invasive cutaneous squamous cell carcinoma depend on the histopathological grade of differentiation. *Br J Dermatol* 2015;172:1308–15.
- [90] Zalaudek I, Giacomel J, Schmid K, Bondino S, Rosendahl C, Cavicchini S, et al. Dermoscopy of facial actinic keratosis, intraepidermal carcinoma, and invasive squamous cell carcinoma: a progression model. *J Am Acad Dermatol* 2012;66:589–97.
- [91] Rishpon A, Kim N, Scope A, Porges L, Oliviero MC, Braun RP, et al. Reflectance confocal microscopy criteria for squamous cell carcinomas and actinic keratoses. *Arch Dermatol* 2009;145:766–72.
- [92] Manfredini M, Longo C, Ferrari B, Piana S, Benati E, Casari A, et al. Dermoscopic and reflectance confocal microscopy features of cutaneous squamous cell carcinoma. *J Eur Acad Dermatol Venereol* 2017;31:1828–33.
- [93] Dinnes J, Deeks JJ, Chuchu N, Saleh D, Bayliss SE, Takwoingi Y, et al. Reflectance confocal microscopy for diagnosing keratinocyte skin cancers in adults. *Cochrane Database of Syst Rev* 2018;12:CD013191.
- [94] Boone MA, Marneffe A, Suppa M, Miyamoto M, Alarcon I, Hofmann-Wellenhof R, et al. High-definition optical coherence tomography algorithm for the discrimination of actinic keratosis from normal skin and from squamous cell carcinoma. *J Eur Acad Dermatol Venereol* 2015;29:1606–15.
- [95] Themstrup L, Pellacani G, Welzel J, Holmes J, Jemec GBE, Ulrich M. In vivo microvascular imaging of cutaneous actinic keratosis, Bowen's disease and squamous cell carcinoma using dynamic optical coherence tomography. *J Eur Acad Dermatol Venereol* 2017;31:1655–62.
- [96] Ferrante di Ruffano L, Dinnes J, Deeks JJ, Chuchu N, Bayliss SE, Davenport C, et al. Optical coherence tomography for diagnosing skin cancer in adults. *Cochrane Database of Syst Rev* 2018;12:CD013189.
- [97] Cheng JY, Li FY, Ko CJ, Colegio OR. Cutaneous squamous cell carcinomas in solid organ transplant recipients compared with immunocompetent patients. *JAMA Dermatol* 2018;154:60–6.
- [98] Kallini JR, Hamed N, Khachemoune A. Squamous cell carcinoma of the skin: epidemiology, classification, management, and novel trends. *Int J Dermatol* 2015;54:130–40.
- [99] Beer TW, Shepherd P, Theaker JM. Ber EP4 and epithelial membrane antigen aid distinction of basal cell, squamous cell and basosquamous carcinomas of the skin. *Histopathology* 2000;37:218–23.
- [100] Breuninger H, Schaumburg-Lever G, Holzschuh J, Horny HP. Desmoplastic squamous cell carcinoma of skin and vermilion surface: a highly malignant subtype of skin cancer. *Cancer* 1997;79:915–9.
- [101] Carter JB, Johnson MM, Chua TL, Karia PS, Schmults CD. Outcomes of primary cutaneous squamous cell carcinoma with perineural invasion: an 11-year cohort study. *JAMA Dermatol* 2013;149:35–41.
- [102] Hillen U, Leiter U, Haase S, Kaufmann R, Becker J, Gutzmer R, et al. Advanced cutaneous squamous cell carcinoma: A retrospective analysis of patient profiles and treatment patterns—Results of a non-interventional study of the DeCOG. *Eur J Cancer* 2018;96:34–43.
- [103] Quaadvlieg PJ, Creytens DH, Epping GG, Peutz-Kootstra CJ, Nieman FH, Thissen MR, et al. Histopathological characteristics of metastasizing squamous cell carcinoma of the skin and lips. *Histopathology* 2006;49:256–64.
- [104] Marrazzo G, Zitelli JA, Brodland D. Clinical outcomes in high-risk squamous cell carcinoma patients treated with Mohs micrographic surgery alone. *J Am Acad Dermatol* 2019;80:633–8.
- [105] Cherpelis BS, Marcusen C, Lang PG. Prognostic factors for metastasis in squamous cell carcinoma of the skin. *Dermatol Surg* 2002;28:268–73.
- [106] Petter G, Hausteil UF. Squamous cell carcinoma of the skin—histopathological features and their significance for the clinical outcome. *J Eur Acad Dermatol Venereol* 1998;11:37–44.
- [107] Karia PS, Morgan FC, Ruiz ES, Schmults CD. Clinical and incidental perineural invasion of cutaneous squamous cell carcinoma: A systematic review and pooled analysis of outcomes data. *JAMA Dermatol* 2017;153:781–8.
- [108] Jambusaria-Pahlajani A, Kanetsky PA, Karia PS, Hwang WT, Gelfand JM, Whalen FM, et al. Evaluation of AJCC tumor staging for cutaneous squamous cell carcinoma and a proposed alternative tumor staging system. *JAMA Dermatol* 2013;149:402–10.
- [109] Breuninger H, Brantsch K, Eigentler T, Hafner HM. Comparison and evaluation of the current staging of cutaneous carcinomas. *Journal der Deutschen Dermatologischen Gesellschaft = J German Soc Dermatol : JDDG.* 2012;10:579–86.
- [110] Karia PS, Morgan FC, Califano JA, Schmults CD. Comparison of tumor classifications for cutaneous squamous cell carcinoma of the head and neck in the 7th vs 8th edition of the AJCC cancer staging manual. *JAMA Dermatol* 2018;154:175–81.
- [111] Sood A, Wykes J, Roshan D, Wang LY, McGuinness J, Fowler A, et al. A critical analysis of the prognostic performance of the 8th edition American Joint Committee on cancer staging for metastatic cutaneous squamous cell carcinoma of the head and neck. *Head Neck* 2019;41:1591–6.
- [112] Liu J, Ebrahimi A, Low TH, Gao K, Palme CE, Sydney C, et al. Predictive value of the 8th edition American Joint Commission Cancer (AJCC) nodal staging system for patients with cutaneous squamous cell carcinoma of the head and neck. *J Surg Oncol* 2018;117:765–72.
- [113] Moeckelmann N, Ebrahimi A, Dirven R, Liu J, Low TH, Gupta R, et al. Analysis and comparison of the 8th edition American Joint Committee on Cancer (AJCC) nodal staging system in cutaneous and oral squamous cell cancer of the head and neck. *Ann Surg Oncol* 2018;25:1730–6.
- [114] Karia PS, Jambusaria-Pahlajani A, Harrington DP, Murphy GF, Qureshi AA, Schmults CD. Evaluation of American Joint Committee on Cancer, international union against cancer, and brigham and women's hospital tumor staging for cutaneous squamous cell carcinoma. *J Clin Oncol* 2014;32:327–34.
- [115] Roscher I, Falk RS, Vos L, Clausen OPF, Helsing P, Gjersvik P, et al. Validating 4 staging systems for cutaneous squamous cell carcinoma using population-based data: A nested case-control study. *JAMA Dermatol* 2018;154:428–34.
- [116] Abraham I, Curiel-Lewandrowski C. Staging systems to predict metastatic cutaneous squamous cell carcinoma: unsatisfactory for clinical use, but some less so? *JAMA Dermatol* 2018;154:1391–2.
- [117] Ruiz ES, Karia PS, Besaw R, Schmults CD. Performance of the American Joint Committee on cancer staging manual, 8th edition vs the brigham and women's hospital tumor classification

- system for cutaneous squamous cell carcinoma. *JAMA Dermatol* 2019;155:819–25.
- [118] Inda JJ, Kabat BF, Larson MC, Slager SL, Baum CL. Comparison of tumor staging systems for cutaneous squamous cell carcinoma in patients with chronic lymphocytic leukemia. *J Am Acad Dermatol* 2019;80:639–45.
- [119] Fox M, Brown M, Golda N, Goldberg D, Miller C, Pugliano-Mauro M, et al. Nodal staging of high-risk cutaneous squamous cell carcinoma. *J Am Acad Dermatol* 2019;81:548–57.
- [120] Gurney B, Newlands C. Management of regional metastatic disease in head and neck cutaneous malignancy. 1. Cutaneous squamous cell carcinoma. *Br J Oral Maxillofac Surg* 2014;52:294–300.
- [121] Ruiz ES, Karia PS, Morgan FC, Schmultz CD. The positive impact of radiologic imaging on high-stage cutaneous squamous cell carcinoma management. *J Am Acad Dermatol* 2017;76:217–25.
- [122] de Bondt RB, Nelemans PJ, Hofman PA, Casselman JW, Kremer B, van Engelshoven JM, et al. Detection of lymph node metastases in head and neck cancer: a meta-analysis comparing US, USgFNAC, CT and MR imaging. *Eur J Radiol* 2007;64:266–72.
- [123] Land R, Herod J, Moskovic E, King M, Sohaib SA, Trott P, et al. Routine computerized tomography scanning, groin ultrasound with or without fine needle aspiration cytology in the surgical management of primary squamous cell carcinoma of the vulva. *Int J Gynecol Canc* 2006;16:312–7.
- [124] Humphreys TR, Shah K, Wysong A, Lexa F, MacFarlane D. The role of imaging in the management of patients with non-melanoma skin cancer: When is imaging necessary? *J Am Acad Dermatol* 2017;76:591–607.
- [125] Williams LS, Mancuso AA, Mendenhall WM. Perineural spread of cutaneous squamous and basal cell carcinoma: CT and MR detection and its impact on patient management and prognosis. *Int J Radiat Oncol, Biol, Phys* 2001;49:1061–9.
- [126] MacFarlane D, Shah K, Wysong A, Wortsman X, Humphreys TR. The role of imaging in the management of patients with nonmelanoma skin cancer: Diagnostic modalities and applications. *J Am Acad Dermatol* 2017;76:579–88.
- [127] Warren TA, Panizza B, Porceddu SV, Gandhi M, Patel P, Wood M, et al. Outcomes after surgery and postoperative radiotherapy for perineural spread of head and neck cutaneous squamous cell carcinoma. *Head Neck* 2016;38:824–31.
- [128] Gandhi MR, Panizza B, Kennedy D. Detecting and defining the anatomic extent of large nerve perineural spread of malignancy: comparing "targeted" MRI with the histologic findings following surgery. *Head Neck* 2011;33:469–75.
- [129] Panizza B, Solares CA, Redmond M, Parmar P, O'Rourke P. Surgical resection for clinical perineural invasion from cutaneous squamous cell carcinoma of the head and neck. *Head Neck* 2012;34:1622–7.
- [130] Navarrete-Dechent C, Veness MJ, Droppelmann N, Uribe P. High-risk cutaneous squamous cell carcinoma and the emerging role of sentinel lymph node biopsy: A literature review. *J Am Acad Dermatol* 2015;73:127–37.
- [131] Sahn RE, Lang PG. Sentinel lymph node biopsy for high-risk nonmelanoma skin cancers. *Dermatol Surg* 2007;33:786–92. discussion 92-3.
- [132] Krediet JT, Beyer M, Lenz K, Ulrich C, Lange-Asschenfeldt B, Stockfleth E, et al. Sentinel lymph node biopsy and risk factors for predicting metastasis in cutaneous squamous cell carcinoma. *Br J Dermatol* 2015;172:1029–36.
- [133] Gore SM, Shaw D, Martin RC, Kelder W, Roth K, Uren R, et al. Prospective study of sentinel node biopsy for high-risk cutaneous squamous cell carcinoma of the head and neck. *Head Neck* 2016;38(Suppl 1):E884–9.
- [134] Fukushima S, Masuguchi S, Igata T, Harada M, Aoi J, Miyashita A, et al. Evaluation of sentinel node biopsy for cutaneous squamous cell carcinoma. *J Dermatol* 2014;41:539–41.
- [135] Reschly MJ, Messina JL, Zaulyanov LL, Cruse W, Fenske NA. Utility of sentinel lymphadenectomy in the management of patients with high-risk cutaneous squamous cell carcinoma. *Dermatol Surg* 2003;29:135–40.
- [136] Allen JE, Stolle LB. Utility of sentinel node biopsy in patients with high-risk cutaneous squamous cell carcinoma. *Eur J Surg Oncol* 2015;41:197–200.
- [137] Schmitt AR, Brewer JD, Bordeaux JS, Baum CL. Staging for cutaneous squamous cell carcinoma as a predictor of sentinel lymph node biopsy results: meta-analysis of American Joint Committee on Cancer criteria and a proposed alternative system. *JAMA Dermatol* 2014;150:19–24.
- [138] Ross AS, Schmultz CD. Sentinel lymph node biopsy in cutaneous squamous cell carcinoma: a systematic review of the English literature. *Dermatol Surg* 2006;32:1309–21.
- [139] Renzi C, Caggiati A, Mannooranparampil TJ, Passarelli F, Tartaglione G, Pennasilico GM, et al. Sentinel lymph node biopsy for high risk cutaneous squamous cell carcinoma: case series and review of the literature. *Eur J Surg Oncol* 2007;33:364–9.
- [140] Tejera-Vaquerizo A, Garcia-Doval I, Llombart B, Canueto J, Martorell-Calatayud A, Descalzo-Gallego MA, et al. Systematic review of the prevalence of nodal metastases and the prognostic utility of sentinel lymph node biopsy in cutaneous squamous cell carcinoma. *J Dermatol* 2018;45:781–90.
- [141] Lhote R, Lambert J, Lejeune J, Gottlieb J, Badaoui A, Battistella M, et al. Sentinel lymph node biopsy in cutaneous squamous cell carcinoma series of 37 cases and systematic review of the literature. *Acta Derm Venereol* 2018;98:671–6.
- [142] Saraiya M, Glanz K, Briss PA, Nichols P, White C, Das D, et al. Interventions to prevent skin cancer by reducing exposure to ultraviolet radiation: A systematic review. *Am J Prev Med* 2004;27:422–66.
- [143] Jackson KM, Aiken LS. Evaluation of a multicomponent appearance-based sun-protective intervention for young women: uncovering the mechanisms of program efficacy. *Health Psychol* 2006;25:34–46.
- [144] Gordon LG, Rowell D. Health system costs of skin cancer and cost-effectiveness of skin cancer prevention and screening: a systematic review. *Eur J Cancer Prev* 2015;24:141–9.
- [145] Henrikson NB, Morrison CC, Blasi PR, Nguyen M, Shibuya KC, Patnode CD. Behavioral counseling for skin cancer prevention: evidence report and systematic review for the US preventive services task force. *JAMA* 2018;319:1143–57.
- [146] Sandhu PK, Elder R, Patel M, Saraiya M, Holman DM, Perna F, et al. Community-wide interventions to prevent skin cancer: Two community guide systematic reviews. *Am J Prev Med* 2016;51:531–9.
- [147] Glanz K, Steffen AD, Schoenfeld E, Tappe KA. Randomized trial of tailored skin cancer prevention for children: the project SCAPE family study. *J Health Commun* 2013;18:1368–83.
- [148] Youl PH, Soyer HP, Baade PD, Marshall AL, Finch L, Janda M. Can skin cancer prevention and early detection be improved via mobile phone text messaging? A randomised, attention control trial. *Prev Med* 2015;71:50–6.
- [149] Green A, Williams G, Neale R, Hart V, Leslie D, Parsons P, et al. Daily sunscreen application and betacarotene supplementation in prevention of basal-cell and squamous-cell carcinomas of the skin: a randomised controlled trial. *Lancet (London, England)* 1999;354:723–9.
- [150] van der Pols JC, Williams GM, Pandeya N, Logan V, Green AC. Prolonged prevention of squamous cell carcinoma of the skin by regular sunscreen use. *Canc Epidemiol Biomarkers Prev* 2006;15:2546–8.
- [151] Silva ESD, Tavares R, Paulitsch FDS, Zhang L. Use of sunscreen and risk of melanoma and non-melanoma skin cancer: a systematic review and meta-analysis. *Eur J Dermatol* 2018;28:186–201.
- [152] Diepgen TL. New developments in occupational dermatology. *Journal der Deutschen Dermatologischen Gesellschaft = J German Soc Dermatol: JDDG* 2016;14:875–89.

- [153] International Commission on Non-Ionizing Radiation P. ICNIRP statement—Protection of workers against ultraviolet radiation. *Health Phys* 2010;99:66–87.
- [154] Kim C, Cheng J, Colegio OR. Cutaneous squamous cell carcinomas in solid organ transplant recipients: emerging strategies for surveillance, staging, and treatment. *Semin Oncol* 2016;43:390–4.
- [155] Harwood CA, Mesher D, McGregor JM, Mitchell L, Leedham-Green M, Raftery M, et al. A surveillance model for skin cancer in organ transplant recipients: a 22-year prospective study in an ethnically diverse population. *Am J Transpl: Off J Am Soc Transpl Am Soc Transpl Surg* 2013;13:119–29.
- [156] Crane LA, Deas A, Mokrohisky ST, Ehrsam G, Jones RH, Dellavalle R, et al. A randomized intervention study of sun protection promotion in well-child care. *Prev Med* 2006;42:162–70.
- [157] Glasser A, Shaheen M, Glenn BA, Bastani R. The sun sense study: an intervention to improve sun protection in children. *Am J Health Behav* 2010;34:500–10.
- [158] Norman GJ, Adams MA, Calfas KJ, Covin J, Sallis JF, Rossi JS, et al. A randomized trial of a multicomponent intervention for adolescent sun protection behaviors. *Arch Pediatr Adolesc Med* 2007;161:146–52.
- [159] Montague M, Borland R, Sinclair C. Slip! Slop! Slap! and Sun-Smart, 1980–2000: Skin cancer control and 20 years of population-based campaigning. *Health Educ Behav* 2001;28:290–305.
- [160] Aulbert W, Parpart C, Schulz-Hornbostel R, Hinrichs B, Kruger-Corcoran D, Stockfleth E. Certification of sun protection practices in a German child day-care centre improves children's sun protection—the 'SunPass' pilot study. *Br J Dermatol* 2009;161(Suppl 3):5–12.
- [161] Hewitt M, Denman S, Hayes L, Pearson J, Wallbanks C. Evaluation of 'Sun-safe': a health education resource for primary schools. *Health Educ Res* 2001;16:623–33.
- [162] Miller DR, Geller AC, Wood MC, Lew RA, Koh HK. The Falmouth Safe Skin Project: evaluation of a community program to promote sun protection in youth. *Health Educ Behav* 1999;26:369–84.
- [163] Nemer KM, Council ML. Topical and systemic modalities for chemoprevention of nonmelanoma skin cancer. *Dermatol Clin* 2019;37:287–95.
- [164] Kadakia KC, Barton DL, Loprinzi CL, Sloan JA, Otley CC, Diekmann BB, et al. Randomized controlled trial of acitretin versus placebo in patients at high-risk for basal cell or squamous cell carcinoma of the skin (North Central Cancer Treatment Group Study 969251). *Cancer* 2012;118:2128–37.
- [165] Nijsten TE, Stern RS. Oral retinoid use reduces cutaneous squamous cell carcinoma risk in patients with psoriasis treated with psoralen-UVA: a nested cohort study. *J Am Acad Dermatol* 2003;49:644–50.
- [166] Anforth R, Blumetti TC, Clements A, Kefford R, Long GV, Fernandez-Penas P. Systemic retinoids for the chemoprevention of cutaneous squamous cell carcinoma and verrucal keratosis in a cohort of patients on BRAF inhibitors. *Br J Dermatol* 2013;169:1310–3.
- [167] Harwood CA, Leedham-Green M, Leigh IM, Proby CM. Low-dose retinoids in the prevention of cutaneous squamous cell carcinomas in organ transplant recipients: a 16-year retrospective study. *Arch Dermatol* 2005;141:456–64.
- [168] Chen K, Craig JC, Shumack S. Oral retinoids for the prevention of skin cancers in solid organ transplant recipients: a systematic review of randomized controlled trials. *Br J Dermatol* 2005;152:518–23.
- [169] Damian DL, Patterson CR, Stapelberg M, Park J, Barnetson RS, Halliday GM. UV radiation-induced immunosuppression is greater in men and prevented by topical nicotinamide. *J Invest Dermatol* 2008;128:447–54.
- [170] Chen AC, Martin AJ, Choy B, Fernandez-Penas P, Dalziel RA, McKenzie CA, et al. A phase 3 randomized trial of nicotinamide for skin-cancer chemoprevention. *N Engl J Med* 2015;373:1618–26.
- [171] Chen AC, Martin AJ, Dalziel RA, McKenzie CA, Lowe PM, Eris JM, et al. A phase II randomized controlled trial of nicotinamide for skin cancer chemoprevention in renal transplant recipients. *Br J Dermatol* 2016;175:1073–5.
- [172] Yelamos O, Halpern AC, Weinstock MA. Reply to 'A phase II randomized controlled trial of nicotinamide for skin cancer chemoprevention in renal transplant recipients'. *Br J Dermatol* 2017;176:551–2.
- [173] Damian DL, Martin AJ, Scolyer RA, Chen AC, Halliday GM. Authors' response to a reply to 'A phase II randomized controlled trial of nicotinamide for skin cancer chemoprevention in renal transplant recipients'. *Br J Dermatol* 2017;176:552–3.
- [174] Muranushi C, Olsen CM, Pandeya N, Green AC. Aspirin and nonsteroidal anti-inflammatory drugs can prevent cutaneous squamous cell carcinoma: a systematic review and meta-analysis. *J Invest Dermatol* 2015;135:975–83.
- [175] Reinau D, Surber C, Jick SS, Meier CR. Nonsteroidal anti-inflammatory drugs and the risk of nonmelanoma skin cancer. *Int J Cancer* 2015;137:144–53.
- [176] Pandeya N, Olsen CM, Thompson BS, Dusingize JC, Neale RE, Green AC, et al. Aspirin and nonsteroidal anti-inflammatory drug use and keratinocyte cancers: a large population-based cohort study of skin cancer in Australia. *Br J Dermatol* 2019;181:749–60.
- [177] Tang JY, Fu T, Leblanc E, Manson JE, Feldman D, Linos E, et al. Calcium plus vitamin D supplementation and the risk of nonmelanoma and melanoma skin cancer: post hoc analyses of the women's health initiative randomized controlled trial. *J Clin Oncol* 2011;29:3078–84.
- [178] Weinstock MA, Thwin SS, Siegel JA, Marcolivio K, Means AD, Leader NF, et al. Chemoprevention of basal and squamous cell carcinoma with a single course of fluorouracil, 5%, cream: A randomized clinical trial. *JAMA Dermatol* 2018;154:167–74.
- [179] Rosenberg AR, Tabacchi M, Ngo KH, Wallendorf M, Rosman IS, Cornelius LA, et al. Skin cancer precursor immunotherapy for squamous cell carcinoma prevention. *JCI Insight* 2019;4.
- [180] Weinstock MA, Bingham SF, Digiiovanna JJ, Rizzo AE, Marcolivio K, Hall R, et al. Tretinoin and the prevention of keratinocyte carcinoma (Basal and squamous cell carcinoma of the skin): a veterans affairs randomized chemoprevention trial. *J Invest Dermatol* 2012;132:1583–90.
- [181] Asgari MM, Arron ST, Warton EM, Quesenberry Jr CP, Weisshaar D. Sirolimus use and risk of cutaneous squamous cell carcinoma (SCC) in solid organ transplant recipients (SOTRs). *J Am Acad Dermatol* 2015;73:444–50.
- [182] Campbell SB, Walker R, Tai SS, Jiang Q, Russ GR. Randomized controlled trial of sirolimus for renal transplant recipients at high risk for nonmelanoma skin cancer. *Am J Transplant* 2012;12:1146–56.
- [183] Knoll GA, Kokolo MB, Mallick R, Beck A, Buenaventura CD, Ducharme R, et al. Effect of sirolimus on malignancy and survival after kidney transplantation: systematic review and meta-analysis of individual patient data. *BMJ* 2014;349:g6679.
- [184] Dantal J, Morelon E, Rostaing L, Goffin E, Brocard A, Tromme I, et al. Sirolimus for Secondary Prevention of Skin Cancer in Kidney Transplant Recipients: 5-Year Results. *J Clin Oncol* 2018;36:2612–20.
- [185] Blomberg M, He SY, Harwood C, Arron ST, Demehri S, Green A, et al. Research gaps in the management and prevention of cutaneous squamous cell carcinoma in organ transplant recipients. *Br J Dermatol* 2017;177:1225–33.
- [186] Bonerandi JJ, Beauvillain C, Caquent L, Chassagne JF, Chaussade V, Clavere P, et al. Guidelines for the diagnosis and treatment of cutaneous squamous cell carcinoma and precursor lesions. *J Eur Acad Dermatol Venereol* 2011;25(Suppl 5):1–51.