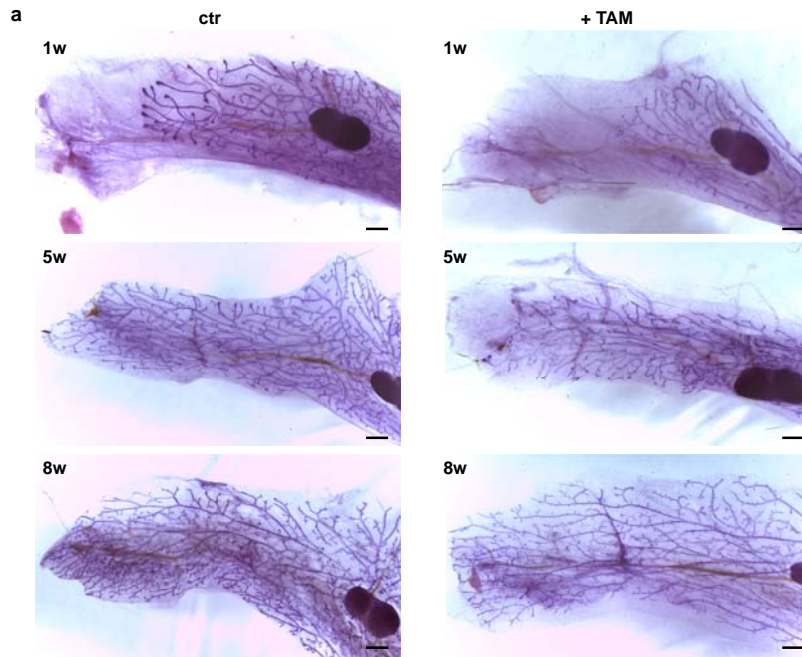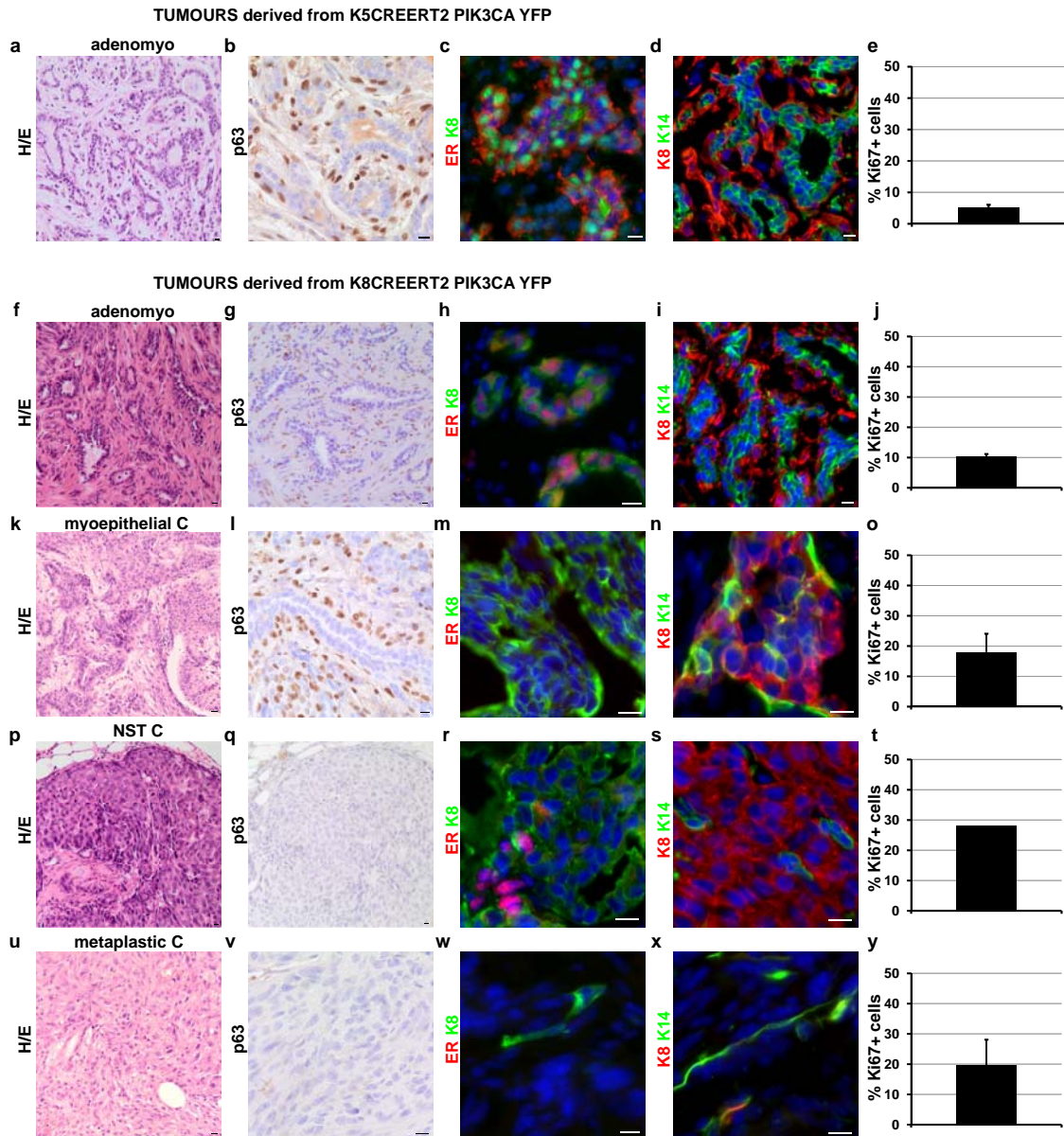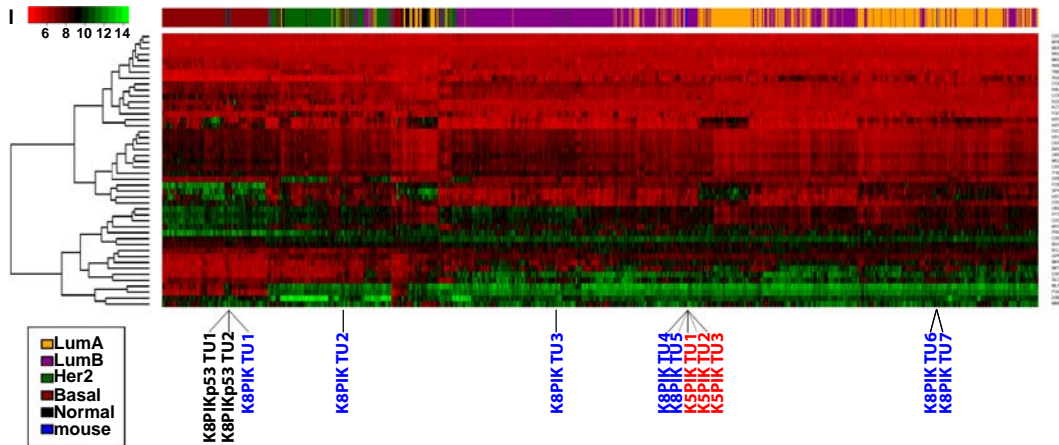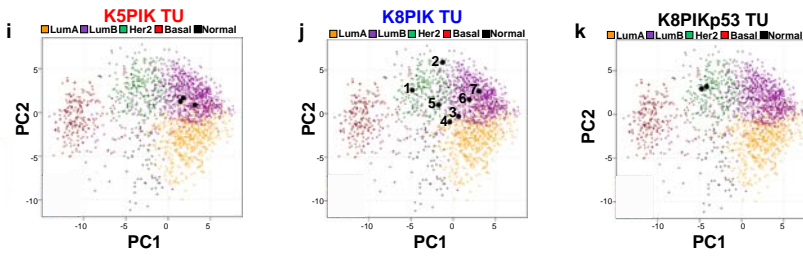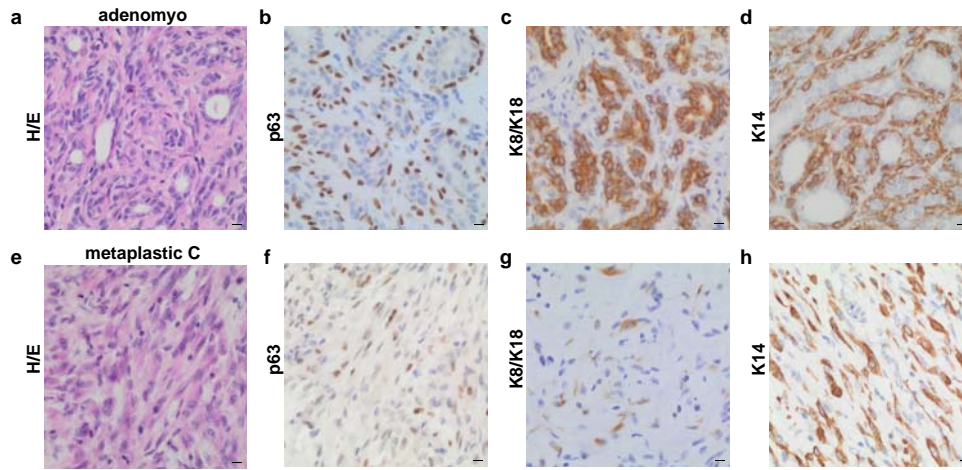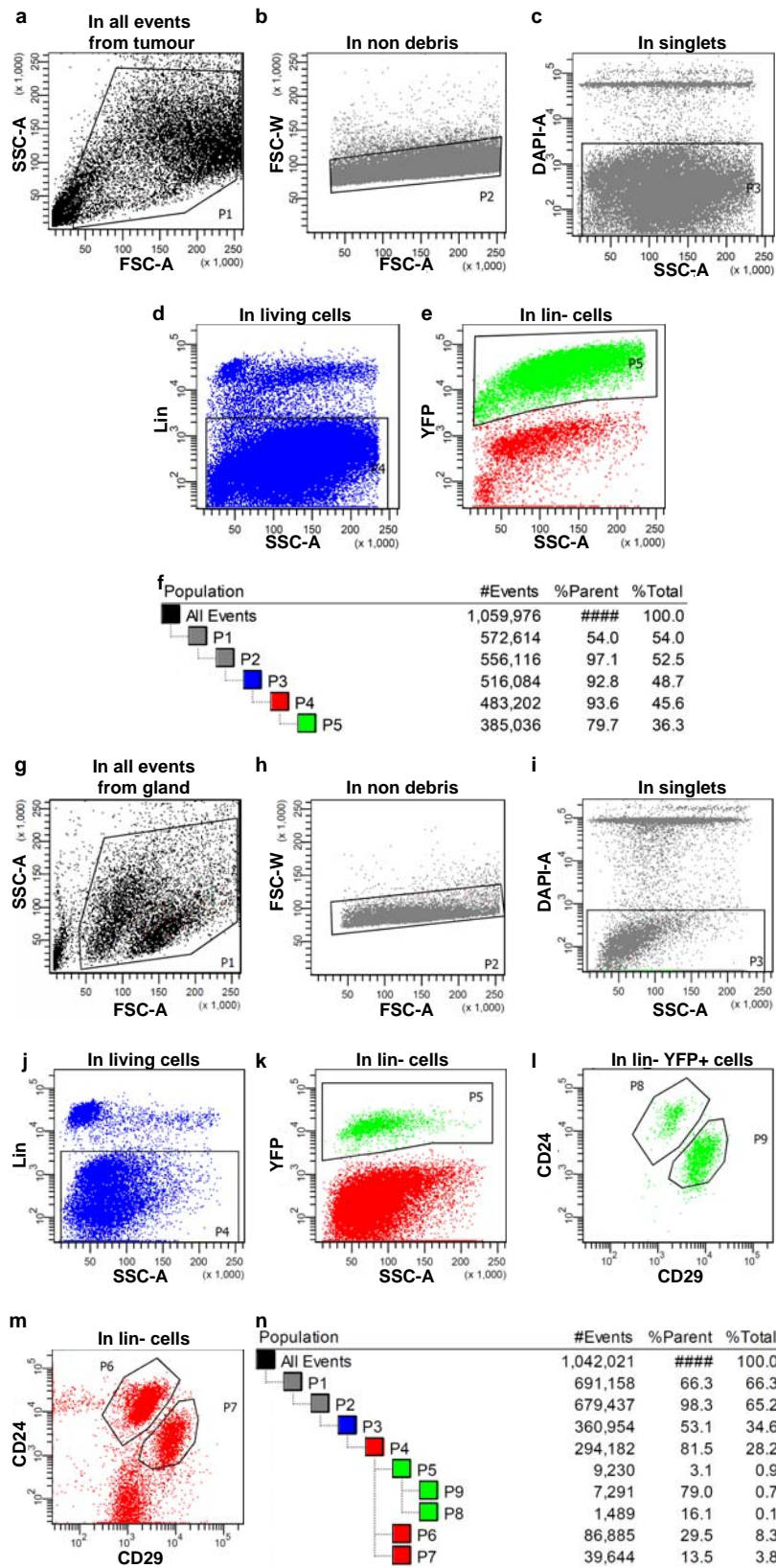
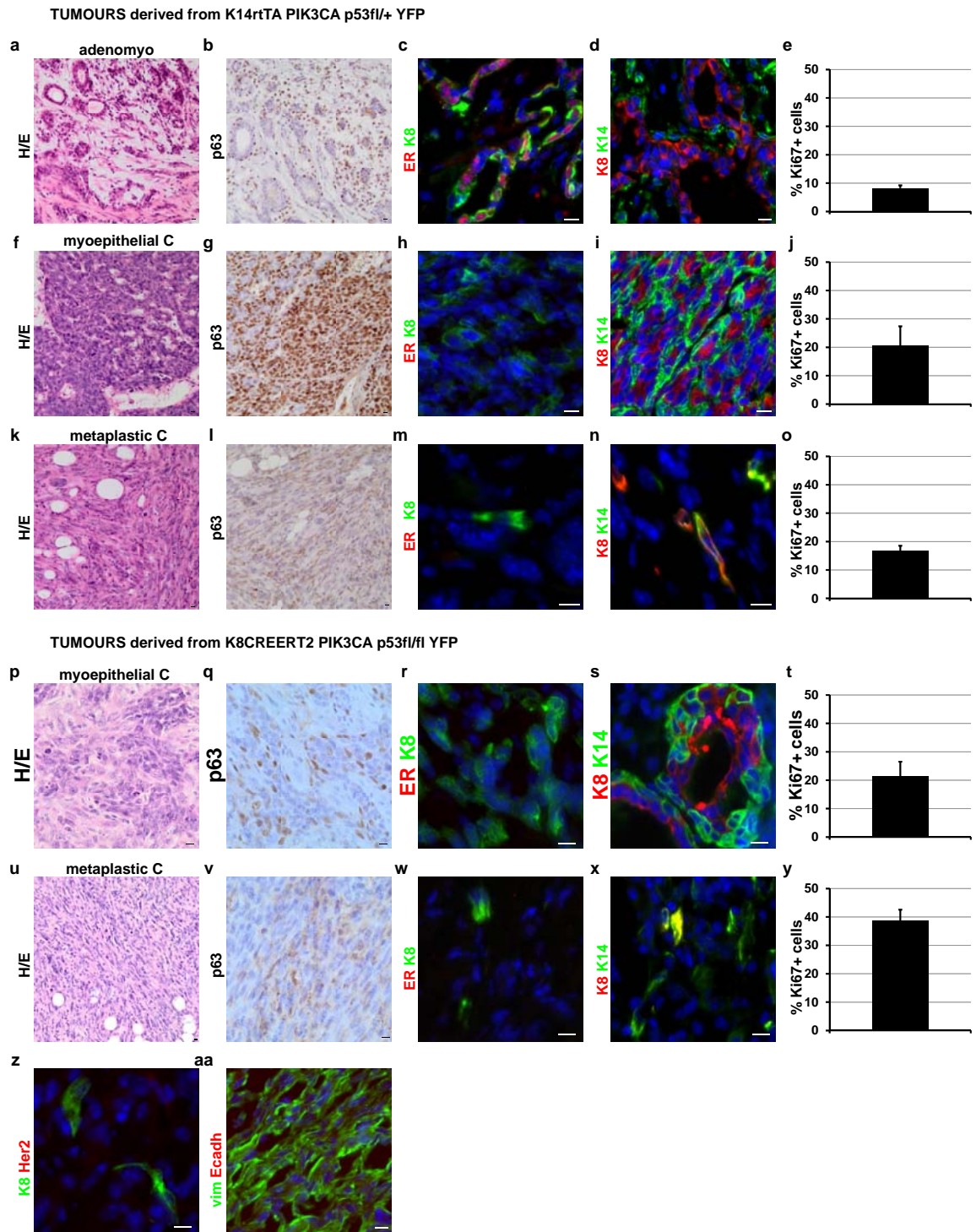
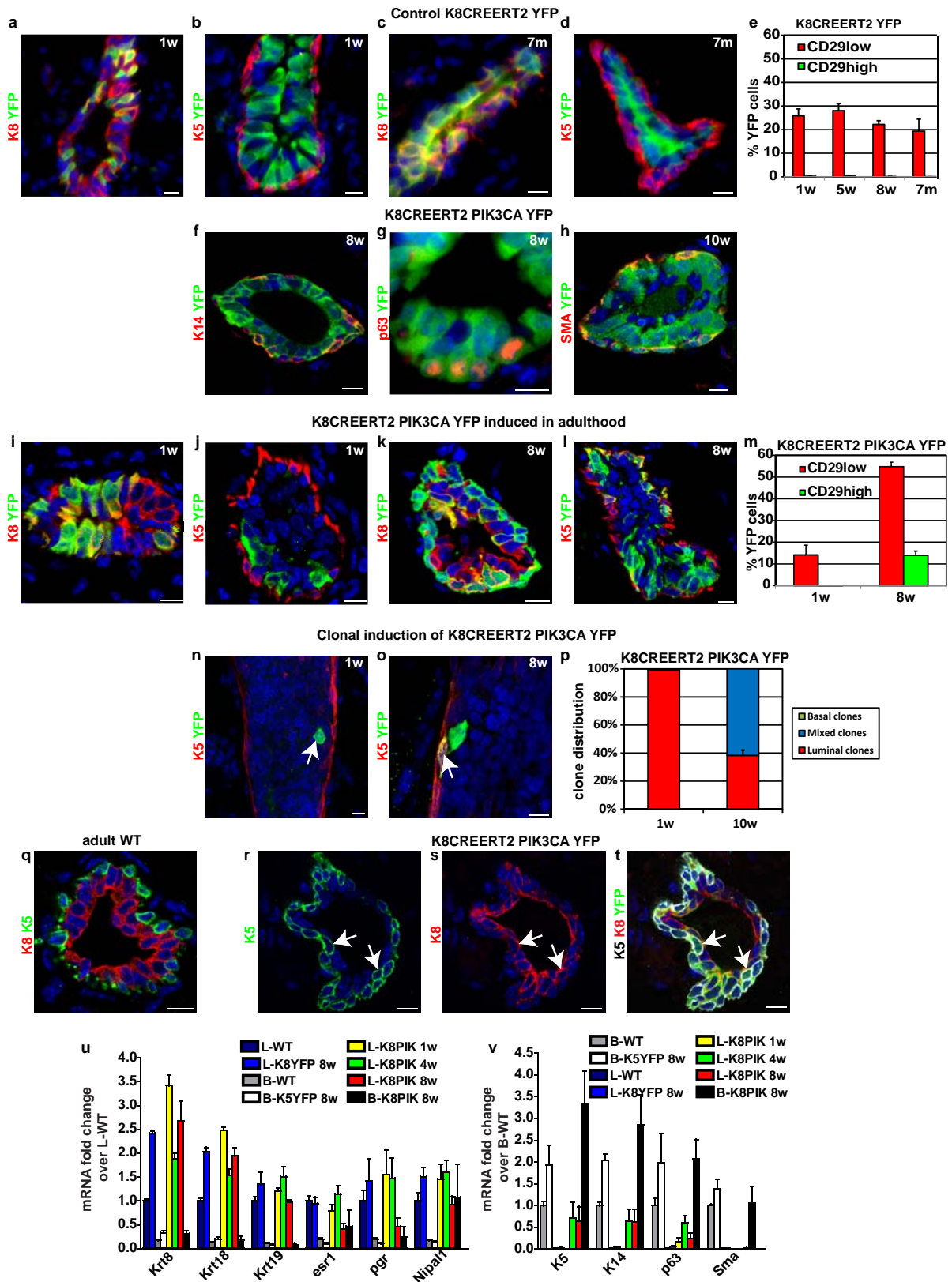


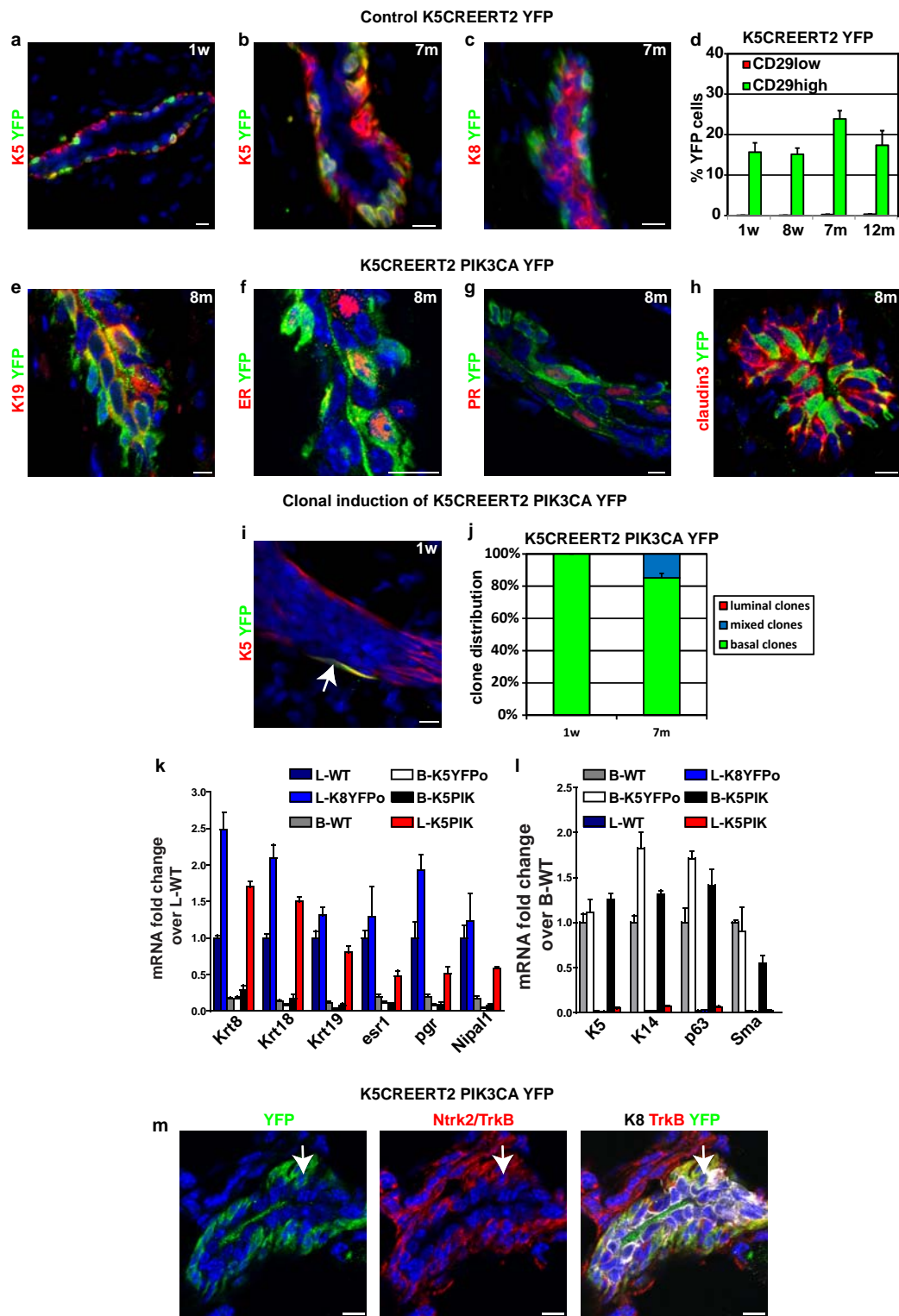
Histological classification of tumours shown

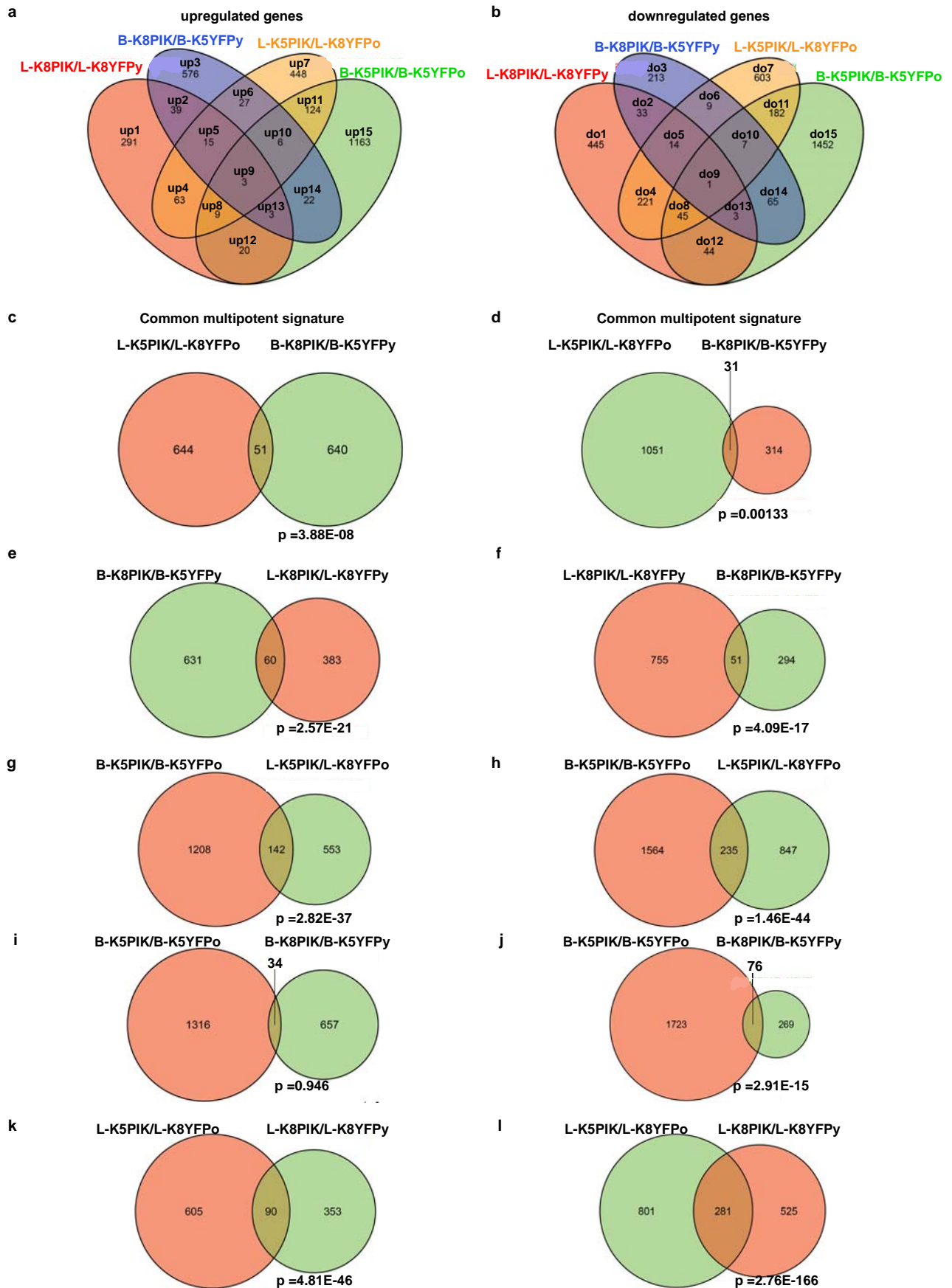
- K5PIK TU1 adenomyoepithelioma
- K5PIK TU2 adenomyoepithelioma
- K5PIK TU3 adenomyoepithelioma
- K8PIK TU1 myoepithelial carcinoma
- K8PIK TU2 invasive carcinoma NST
- K8PIK TU3 metaplastic carcinoma with mesenchymal differentiation
- K8PIK TU4 adenomyoepithelioma
- K8PIK TU5 adenomyoepithelioma
- K8PIK TU6 adenomyoepithelioma+ myoepithelial carcinoma
- K8PIK TU7 adenomyoepithelioma
- K8PIKp53 TU1 metaplastic carcinoma with mesenchymal differentiation
- K8PIKp53 TU2 metaplastic carcinoma with mesenchymal differentiation

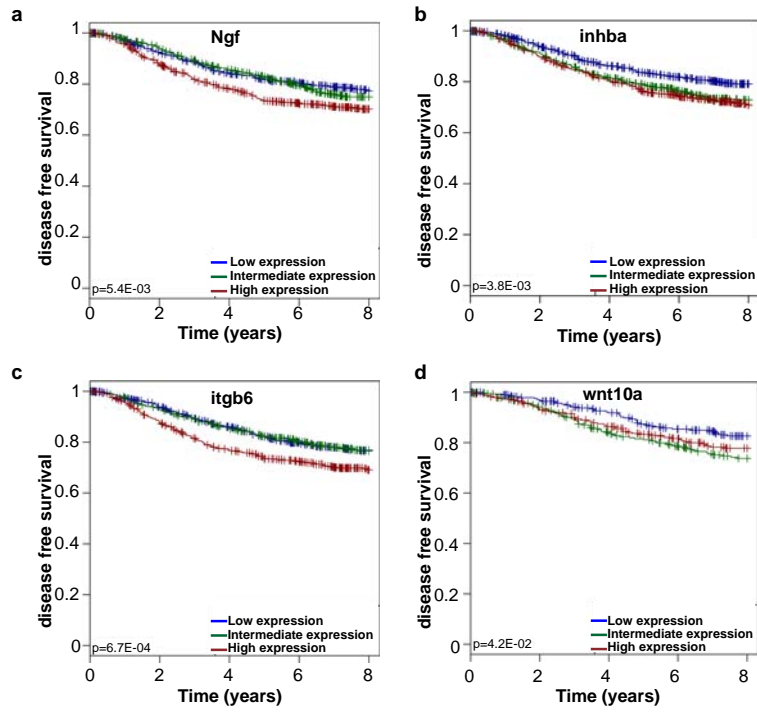












Van Keymeulen et al, Extended data Figure 9